

Original Article

Testicular Morphology and Sperm Motility in Cultured African Catfish (*Clarias gariepinus*) at Different Stages of Development

Chidozie N. OKOYE¹, Udensi M. IGWEBUIKE², Anietie F. UDOUMOH^{2*},
Chinadindu T. OKEREKE¹

¹University of Nigeria, Faculty of Veterinary Medicine, Department of Veterinary Obstetrics and Reproductive Diseases, Nsukka, Nigeria; chidozie.okoye@unn.edu.ng

²University of Nigeria, Faculty of Veterinary Medicine, Department of Veterinary Anatomy, Nsukka, Nigeria; udensi.igwebuike@unn.edu.ng;

anietie.udoumoh@unn.edu.ng; okerekechinadindu@yahoo.com

Abstract

Testicular morphology and sperm motility were evaluated in cultured *Clarias gariepinus* (n = 25) purposively assigned to five groups according to their age. The results showed that the testes were paired, elongated, dorso-ventrally flattened structures, situated in the caudal aspects of the body cavity. The mean length of both right and left testes increased linearly with age, being significantly ($p < 0.05$) higher at 6 months than at 4 and 5 months of age, and also significantly ($p < 0.05$) higher at 8 months than at 6 months of age, while the mean weight and organo-somatic index of the catfish testes increased linearly until 6 months of age, after which no significant ($p > 0.05$) increase in the testicular weight and organo-somatic index was observed. Unidirectional progressive movement of spermatozoa was detected in the milt of *C. gariepinus* at 6, 7 and 8 months of age, but sperm cells were non-motile at 4 and 5 months of age. Histological sections showed seminiferous lobules, whose germinal epithelia were characterized by many cysts enclosing clones of sperm cells. Each cyst enclosed a clone of sperm cells at an identical stage of spermatogenesis. Spermatids and spermatozoa were present in the lumen of the seminiferous lobule. The obtained results indicate that the morphology of the testes of *C. gariepinus* is similar to the testes of members of the order Siluriformes, but sexual maturity and production of motile spermatozoa may be achieved at 6 months of age in the African catfish.

Keywords: gonadosomatic index, seminiferous lobules, Siluriformes, testicular cysts

Introduction

Catfish is a member of the order Siluriformes, which is the most diverse fish order (Van Dyk and Pieterse, 2008) and many species of fish in this order have been introduced into aquaculture. Catfish culture contributes about 60% of the world's supply of protein (FAO, 2007), especially in developing countries of Africa, where the sharp-tooth catfish (*Clarias gariepinus*) is widely distributed (Nwuba and Aguigwo, 2002). In Nigeria, commercial fish production is a growing enterprise, and catfish farming is the most popular form of fish farming in the country. Understanding the reproductive biology of the catfish is one of the most important factors for improvement of catfish culture, and this is paramount in commercial aquaculture enterprises.

The testes of mature catfish are paired elongated structures located in the dorsal part of the posterior body cavity. The testes may vary in size depending on the age of the fish and the season of the year (Genten *et al.*, 2009), but the left testis is thought to be usually longer than the right one (Van Dyk and Pieterse, 2008). Breeding in catfish is seasonal, and the level of testicular activity and spermatogenesis depend mostly on the light period and temperature (Garg and Sundararaj, 1985).

Hormonal, environmental and genetic manipulations are amongst several strategies developed to influence the sexual maturation of cultured catfish, but there is limited information on the relationship between gonadal development, hormone cycle and spawning (Barrero *et al.*, 2007).

A recent study has suggested that characterization of mature testes and sperm morphology of the fish may have practical applications related to artificial fertilization and sperm preservation (Furbock *et al.*, 2010). However, there is very little information on age-related variations in the morphology of the testes of the African catfish.

The present study investigated the morphological and histological changes in the testes, and sperm motility of the African catfish (*C. gariepinus*) at different ages during development.

Materials and Methods

Experimental animals and sample collection

Clarias gariepinus (n = 25) used in the study were all males obtained from a commercial fish farm located at Ozubulu in Ekwusigbo Local Government Area, Anambra State, Nigeria. They were measured, weighed and purposively assigned to five

groups of five fish each according to their ages. The ages (months) were 4 (mean weight = 112.0 ± 17.4 g and mean length = 24.10 ± 0.39 cm), 5 (mean weight = 178.0 ± 22.2 g and mean length = 28.98 ± 0.85 cm), 6 (mean weight = 780.0 ± 118.9 g and mean length = 50.82 ± 2.71 cm), 7 (mean weight = 856.0 ± 45.4 g and mean length = 51.76 ± 1.01 cm) and 8 (mean weight = 1467.2 ± 37.1 g and mean length = 63.17 ± 2.89 cm). The animals were stunned and dissected to obtain the testes used for the morphological studies. The gonadosomatic indices were determined according to the following formula (Roff, 1983): $GSI = (\text{testicular weight} / \text{total body weight}) \times 100$.

Assessment of sperm motility

Semen collected from each fish was examined under a light microscope for presence of mature spermatozoa. The spermatozoa were visually assessed for unidirectional progressive movement.

Analysis of testes histomorphology

Samples of testes of fish in the five groups were promptly fixed by immersion in Bouin's fluid for 48 h. Later, the fixed specimens were dehydrated in increasing concentrations of ethanol, cleared in two changes of xylene, and embedded in paraffin wax. Then, $5 \mu\text{m}$ thick sections were cut, mounted on glass slides and stained routinely with haematoxylin and eosin (H & E) for light microscopy. Photomicrographs were captured using a Moticam Images Plus 2.0 digital camera (Motic China Group Ltd.).

Statistical analyses

Data obtained for the quantitative parameters were expressed as mean \pm standard error of mean. These were subjected to one-way analysis of variance (ANOVA). Variant means were separated post-hoc using the least significant difference (LSD) method.

Results

Gross anatomy

The testes of *C. gariepinus* were paired elongated, dorso-ventrally flattened structures situated just beneath the dorsal body wall in the caudal aspects of the body cavity. They were attached to the dorsal body wall by the mesorchium. The medial border of each testis was smooth, while the lateral border exhibited serrated edges (Fig. 1).

Quantitative parameters

Data on mean length of the fish, as well as mean length of left and right testes are shown in Table 1. The mean length of the fish was significantly ($p < 0.05$) higher at 6 months than compared with that from 4 and 5 months of age, and also significantly ($p < 0.05$) higher at 8 months compared to 6 and 7 months of age (Table 1). Similarly, the mean length of both right and left testes increased linearly with age, being significantly ($p < 0.05$) higher at 6 months than at 4 and 5 months of age, and also significantly ($p < 0.05$) higher at 8 months than at 6 months of age. The right testis was longer than the left testis at 4, 6 and 7 months of age, but at 8 months of age, the left testis was longer than the right testis.

Table 2 shows information on mean weights of the fish and the testes. The mean weight of the fish followed a

comparable pattern as the mean length of the fish, so that it showed a significantly ($p < 0.05$) higher value at 6 months than at 4 and 5 months of age, and also a significantly ($p < 0.05$) higher value at 8 months compared to 6 and 7 months of age (Table 2). Mean weight of pooled left and right testes increased significantly ($p < 0.05$) from 4 to 6 months of age, after which no significant difference ($p > 0.05$) was observed in the mean weight of the testes with age. Moreover, the mean weight of right testes was greater than that of left testes at 4, 5, 6, and 7 months of age, but at 8 months of age, the mean weight of left testes was greater than that of right testes.

Comparison of the gonadosomatic indices revealed that the mean percentage contribution of pooled left and right testicular weight to the body weight of the fish increased from $0.362 \pm 0.032\%$ at 4 months to attain a peak value of $0.937 \pm 0.047\%$ at 6 months, after which the value decreased to $0.645 \pm 0.312\%$ at 8 months of age (Table 2). The mean gonadosomatic index of the right testes was consistently higher than that of the left testis at 4, 5, 6 and 7 months of age, but the mean gonadosomatic index of the right testes was greater than that of the left testes at 8 months of age.

Sperm motility

Mature spermatozoa were observed in the semen obtained from fish in all the five groups studied. However,

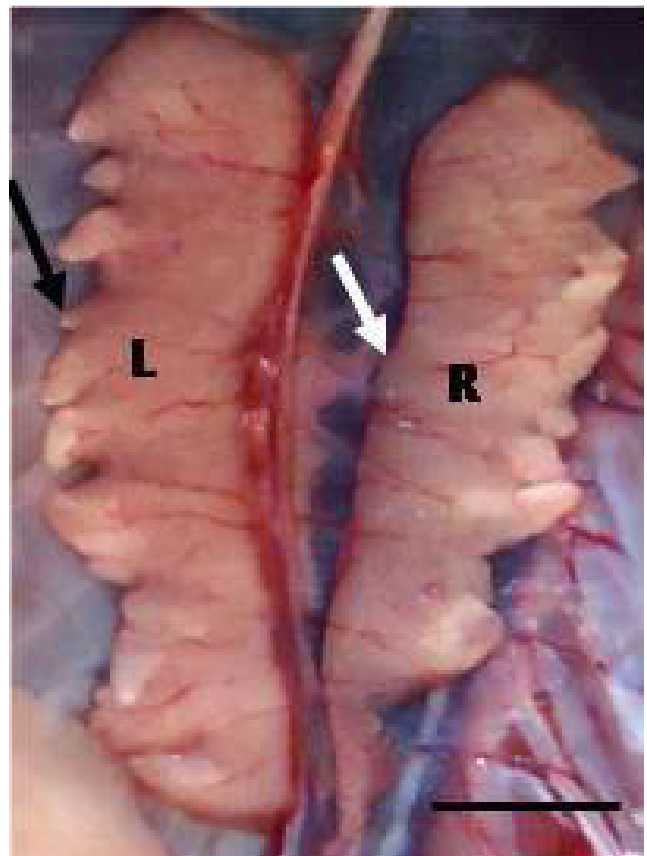


Fig. 1. Testes of *Clarias gariepinus* at 8 months of age. Note: left (L) and right (R) testes with serrated lateral (black arrow) and smooth medial (white arrow) borders. Scale bar = 8 cm

Table 1. Mean length (cm) of *C. gariepinus* and mean lengths (cm) of right and left testes of the fish at different ages

Ages (months)	4	5	6	7	8
Mean length of fish (cm)	24.10 ± 0.39 ^a	28.98 ± 0.85 ^a	50.82 ± 2.71 ^b	51.76 ± 1.01 ^b	63.17 ± 2.89 ^c
Mean length of right testes (cm)	2.26 ± 0.06 ^a	2.68 ± 0.22 ^a	5.70 ± 0.46 ^b	5.44 ± 0.26 ^{bc}	6.50 ± 0.49 ^c
Mean length of left testes (cm)	2.24 ± 0.15 ^a	2.68 ± 0.36 ^a	5.04 ± 0.34 ^b	4.76 ± 0.30 ^b	6.80 ± 1.07 ^c

^{a, b, c} different superscripts in a row indicate statistically significant differences

Table 2. Mean weight (g) of *C. gariepinus*, mean weights (g) and mean gonadosomatic indices (%) of right and left testes of the fish at different ages

Ages (months)	4	5	6	7	8
Mean weight of fish (g)	112.0 ± 17.4 ^a	178.0 ± 22.2 ^a	780.0 ± 118.9 ^b	856.0 ± 45.4 ^b	1467.2 ± 37.1 ^c
Mean weight of pooled left and right testes (g)	0.385 ± 0.042 ^a	0.834 ± 0.249 ^b	7.428 ± 1.351 ^c	6.578 ± 1.542 ^c	9.013 ± 4.315 ^c
Mean weight of right testes (g)	0.198 ± 0.019 ^a	0.430 ± 0.122 ^b	4.528 ± 1.131 ^c	4.303 ± 1.034 ^c	4.471 ± 1.669 ^c
Mean weight of left testes (g)	0.197 ± 0.027 ^a	0.410 ± 0.130 ^b	3.055 ± 0.455 ^c	2.520 ± 0.567 ^c	4.544 ± 2.735 ^c
Mean gonadosomatic index of pooled left and right testes (%)	0.362 ± 0.032 ^a	0.487 ± 0.137 ^a	0.937 ± 0.047 ^b	0.745 ± 0.133 ^c	0.645 ± 0.312 ^a
Mean gonadosomatic index of right testes (%)	0.188 ± 0.018 ^a	0.254 ± 0.068 ^{ab}	0.558 ± 0.077 ^c	0.488 ± 0.090 ^{bc}	0.319 ± 0.122 ^{ab}
Mean gonadosomatic index of left testes (%)	0.181 ± 0.013 ^a	0.237 ± 0.071 ^{ab}	0.396 ± 0.033 ^b	0.286 ± 0.051 ^{ab}	0.326 ± 0.195 ^a

^{a, b, c} different superscripts in a row indicate statistically significant differences

only the spermatozoa of 6, 7 and 8 month old fish showed unidirectional progressive movement under the light microscope. Spermatozoa of the 4 and 5 month old groups were non-motile.

Histology

Photomicrographs of the testes of *C. gariepinus* at 8, 6 and 4 months of age are shown in Figs. 2, 3 and 4 respectively. Each testis was surrounded by a thick connective tissue capsule, the tunica albuginea, which was richly vascularized and exhibited the presence of some adipose cells (Fig. 2). Connective tissue trabeculae from the tunica albuginea penetrated the testicular parenchyma to demarcate compartments, the seminiferous lobules, each of which showed a lumen at its centre. Interstitial tissue composed of connective tissue cells, interstitial cells and blood vessels separated adjacent seminiferous lobules. The germinal epithelium within each seminiferous lobule exhibited several sperm cells at different stages of maturation. The sperm cells were enclosed in several cysts present within the germinal epithelium (Figs. 2, 3, 4). Each cyst enclosed a clone of sperm cells at an identical stage of spermatogenesis. Thus, some cysts enclosed the spermatogonia, while others enclosed the spermatocytes. The nuclei of the spermatocytes were smaller in size and appeared darker than the nuclei of the spermatogonia. Moreover, the cysts containing the spermatogonia were mostly situated close to the base of the epithelium, while the spermatocyte-containing cysts were located in the adluminal region of the germinal epithelium. Spermatids and spermatozoa were seen in the lumen of the

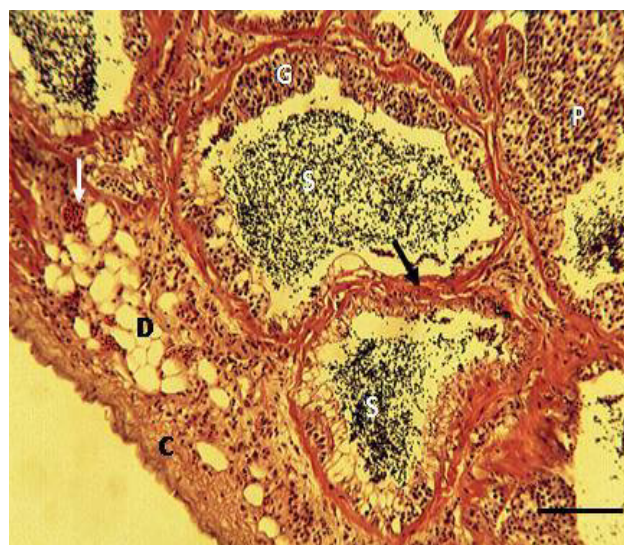


Fig. 2. Testicular histology of *C. gariepinus* at 8 months of age
Note: tunica albuginea (C), blood vessel (white arrow), adipose cells (D), trabeculae (black arrow), spermatozoa (S), spermatocytes (P), spermatogonia (G). H&E stain, objective x10, scale bar = 60 µm.

seminiferous lobule (Figs. 2, 3, 4). The spermatids were distinguished by their very dark nuclei. The seminiferous lobule luminal diameter was apparently larger, and contained more spermatids and spermatozoa at 6 and 8 months of age than at 4 and 5 months of age.

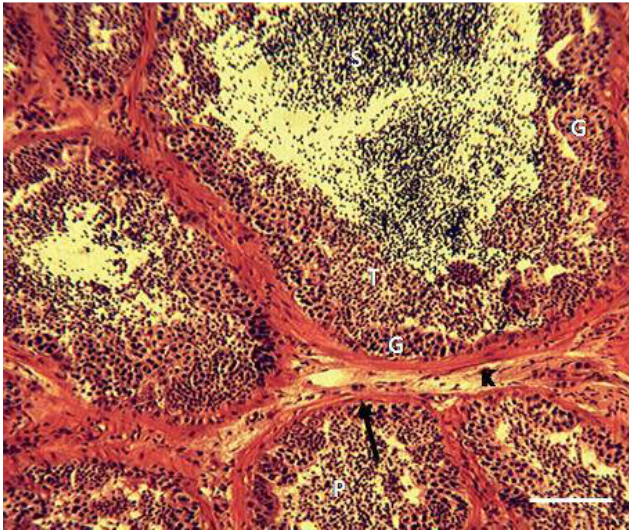


Fig. 3. Testicular histology of *C. gariepinus* at 6 months of age
Note: connective tissue trabeculae (black arrow), cyst-enclosed spermatogonia (G) and spermatocytes (T), spermatids (P), spermatozoa (S), interstitial tissues (K). H&E stain, objective x10, scale bar = 60 μ m.

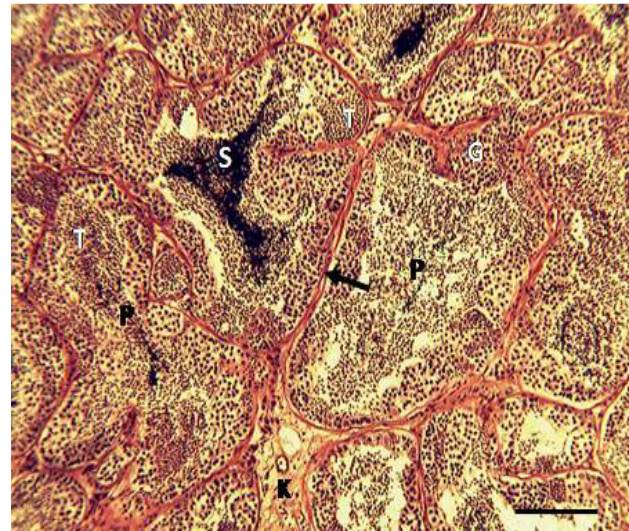


Fig. 4. Testicular histology of *C. gariepinus* at 4 months of age
Note: connective tissue trabeculae (black arrow), cyst-enclosed spermatogonia (G) and spermatocytes (T), spermatids (P), spermatozoa (S), interstitial tissues (K). H&E stain, objective x10, scale bar = 60 μ m.

Discussion

Structural and functional status of the testes and sperm cells are important considerations for successful breeding programs that involve artificial fertilization. Thus, characterization of mature testes and sperm morphology of the catfish may have practical applications in commercial catfish farming. The illustration of paired, elongated, dorso-ventrally flattened testes with serrated lateral borders in the *C. gariepinus* is consistent with the features reported for members of the order Siluriformes, including the Doradidae and the Auchenipteridae families (Meisner *et al.*, 2000). It is apparent from the present study that testicular length may be influenced by the length of the catfish, and both the fish length and length of testes increased linearly with age. Whereas, Ratty *et al.* (1990) reported that the right testes are larger than the left testes in *Thunnus alalunga*, Van Dyk and Pieterse (2008) showed that the left testes of fish are usually longer than the right testes. However, the present study demonstrated that the right testes of *C. gariepinus* were longer than the left testes until 8 months of age, when the left testes grew to be longer than the right testes. This suggests that the dissimilarity in the observations of the previous authors may have resulted from disparity in the ages of the fishes used for their respective studies.

The mean weight and organo-somatic index of the catfish testes increased linearly until 6 months of age, after which no significant increase in the testicular weight and testicular-somatic index was observed. The testes of *Clarias gariepinus* may have attained optimal weight and peak sperm production potential at 6 months of age, since the weight of an organ may be related to its functional status. Indeed, a positive correlation has been established between testicular weight and sperm production, and the gonadosomatic

index has been employed for estimation of reproductive performance of fish (Kumari, 2014). The idea that the catfish testes may have achieved optimal development at 6 months of age is further supported by the finding that spermatozoa with capacity for unidirectional progressive movement were first identified in the milt of *C. gariepinus* at 6 months of age, an indication of sexual maturity in the fish. Sperm motility is considered the best biomarker of milt quality (Lahnsteiner *et al.*, 2004) and it is thought to have great influence on successful fertilization in fish (Oguntuase and Adebayo, 2014).

Histology of the catfish testes demonstrated that the seminiferous epithelium within the seminiferous lobules contained cysts of clones of sperm cells at identical stages of spermatogenesis. It has been shown that the cyst wall is derived from the sertoli cell associated with the original germ cell from which the clone of sperm cells arise (Santos *et al.*, 2001). Cysts of the more mature sperm cells were located in an adluminal position, from where the resulting spermatids may be released into the lumen of the seminiferous lobule. Maturation of spermatids into spermatozoa is thought to take place within the lumen of the seminiferous lobule (Genten *et al.*, 2009), and the asynchronous development of spermatogenesis in the various cysts may support continuous spermatation in cultured *C. gariepinus*. The apparently larger luminal diameter of the seminiferous lobules, and their content of numerous spermatids and spermatozoa at 6 and 8 months of age than at 4 months of age may be related to our proposition that *C. gariepinus* attains sexual maturity at 6 months of age. This suggested age at sexual maturity in the catfish is at variance with the reports of some previous authors (Cek and Yilmaz, 2007). However, genetic factors and culture conditions, including nutrition have been shown to influence the age of maturation of cultured fish (Le Bail, 1996).

Conclusions

The present study has shown that the morphology of the testes of *Clarias gariepinus* is similar to the testes of members of the order siluriformes, but sexual maturity and production of motile spermatozoa may be achieved at 6 months of age in the African catfish.

References

- Barrero M, Small BC, D'Abramo LR, Hanson LA, Kelly AM (2007). Comparison of estradiol, testosterone, vitellogenin and cathepsin profiles among young adult channel catfish (*Ictalurus punctatus*) females from four selectively bred strains. *Aquaculture* 264(1-4):390-397.
- Cek S, Yilmaz E (2007). Gonadal development and sex ratio of sharptooth catfish (*Clarias gariepinus* Burchell, 1822) cultured under laboratory conditions. *Turkish Journal of Zoology* 31(1):35-46.
- Food and Agriculture Organization (2007). The state of world fisheries and aquaculture 2006. FAO Fisheries Department, Rome, Italy.
- Furbock S, Patzner RA, Lahnsteiner F (2010). Fine structure of spermatozoa of *Chondrostoma nasus* and *Rutilus meidingerii* (Teleostei: Cyprinidae) as revealed by scanning and transmission electron microscopy. *Acta Zoologica* 91(1):88-95.
- Garg SK, Sundararaj BI (1985). Response of the testes and seminal vesicles of the catfish, *Heteropneustes fossilis* (Bloch) to various combinations of photoperiod and temperature. *Physiological Zoology* 58:616-627.
- Genten F, Terwinghe E, Danguy A (2009). Atlas of fish histology. Science Publishers, New Hampshire, USA.
- Kumari S (2014). Study on growth and reproductive behaviour in freshwater catfish (*Heteropneustes fossilis*). *Scholars Academic Journal of Bioscience* 2(6):380-383.
- Lahnsteiner F, Berger B, Horvath A, Urbanyi B (2004). Studies on the semen biology and sperm cryopreservation in the Sterlet, *Acipenser ruthenus* L. *Aquaculture Research* 35(6):519-528.
- Le Bail PY (1996). Growth-reproduction interaction in salmonids. In: Reproduction in Fish; Basic and Applied Aspects in Endocrinology and Genetics. Zohar Y, Breton B (Eds). Les Colloques de l'INRA, Paris pp 91-107.
- Meisner AD, Burns JR, Weitzman SH, Malabarba LR (2000). Morphology and histology of the male reproductive system in two species of internally inseminating South American catfishes *Trachelyopterus lucenai* and *T. galeatus* (Teleostei: Auchenipteridae). *Journal of Morphology* 246(2):313-342.
- Nwuba LA, Aguigwo JN (2002). Studies on the effects of different food items on the survival of *Carias anguilaris*. *Journal of Aquatic Science* 17(2):121-124.
- Oguntuase BG, Adebayo OT (2014). Sperm quality and reproductive performance of male *Clarias gariepinus* induced with synthetic hormones (ovotide and ovaprim). *International Journal of Fisheries and Aquaculture* 6(1):9-15.
- Ratty FJ, Laurs RM, Kelly RM (1990). Gonad morphology, histology and spermatogenesis in South Pacific albacore tuna, *Thunnus alalunga* (Scombridae). *Fishery Bulletin* 88(1):207-216.
- Roff DA (1983). An allocation model of growth and reproduction in fish. *Canadian Journal of Fisheries and Aquatic Sciences* 40(9):1395-1404.
- Santos JE, Bazzoli N, Rizzo E, Santos GB (2001). Morpho-functional organization of the male reproductive system of the catfish (*Iheringichthys labrosus* Lutken 1874. Siluriformes: Pimelodidae). *Tissue Cell* 33(5):533-540.
- Van Dyk JC, Pieterse GM (2008). A histo-morphological study of the testis of the sharptooth catfish (*Clarias gariepinus*) as reference for future toxicological assessments. *Journal of Applied Ichthyology* 24(4):415-422.