

***Tetrapleura tetraptera* ethylacetate pod extract and its biochemical effects on acetaminophen-induced hepatotoxic female rat**

Patrick E. ABA*, Marie A. KALU, Samuel C. UDEM

University of Nigeria, Faculty of Veterinary Medicine, Department of Veterinary Physiology and Pharmacology, Nsukka, Nigeria;
Patrick.aba@unn.edu.ng (*corresponding author); marie.kalu189396@unn.edu.ng; Samuel.udem@unn.edu.ng

Abstract

The study investigated the effect of ethyl acetate pod extract of *Tetrapleura tetraptera* on biochemical markers of liver damage, *in vivo* and *in vitro* antioxidant properties using acetaminophen-injured female rats as model. Thirty-five (35) rats assigned into seven groups (A-G) of five rats per group were used for the study. Rats in groups C, D, E and F were pretreated with 100, 200, 400 and 200 mg/kg of the extract while group G rats received Silymarin (100 mg/kg). Distilled water (10 ml/kg) was administered to groups A and B rats. All pretreatments were via the oral route and lasted for seven days. Following pretreatments, acetaminophen (2000 mg/kg) was used to induce liver injury in groups B, C, D, E and G while rats in group A served as normal control. Blood samples were collected 48 h post acetaminophen administration for analyses of the following parameters: Alanine aminotransferase (ALT), alkaline phosphatase (ALP), serum bilirubin, reduced glutathione and superoxide dismutase. Liver tissues were collected for histopathology studies. *In vitro* antioxidant profile of the extract was evaluated. Results indicated decreases in the activities of ALT and ALP of the extract-treated groups compared to the negative control group. The liver section of the rats treated with 400 mg/kg of the extract showed no lesions and was comparable to that of the normal control rats. The *in vivo* and *in vitro* antioxidant activities were in dose and concentration-dependent manner respectively. It was concluded that *Tetrapleura tetraptera* ethyl acetate extract possesses both hepatoprotective and antioxidant properties.

Keywords: antioxidant activity; hepatoprotection; liver damage markers; rats; *Tetrapleura tetraptera*

Introduction

Tetrapleura tetraptera also known in English language as Aidan tree, botanically belongs to the family Fabaceae. It is widely distributed in the tropical African countries cutting across Mauritania through Tanzania (Blay, 1997). Ghananians call it "Prekese" while it is known as "Kikangabakimu" in Uganda (Kemigisha *et al.*, 2018). In Nigeria, the Igbos (Southeastern Nigerians), refer to it as "Uhikiriho/Oshorisho". The Hausas (Northeastern and Northwestern Nigerians) call it "Dawo" while the Yorubas (southwestern Nigerians) named it "Aridan tree". The Igala (Northcentral Nigerians) people call it "Abogolo" (Okwu, 2003). The tree can grow

Received: 26 Apr 2022. Received in revised form: 26 May 2022. Accepted: 01 Jun 2022. Published online: 06 Jun 2022.

From Volume 13, Issue 1, 2021, Notulae Scientia Biologicae journal uses article numbers in place of the traditional method of continuous pagination through the volume. The journal will continue to appear quarterly, as before, with four annual numbers.

as high as 25 m and it is seen mainly in savanna woodlands, riverine areas, dense and dry forests (Kemigisha *et al.*, 2018)

It is both nutritionally and medically important (Adesina *et al.*, 2016). Researchers claim that *Tetrapleura tetraptera* has anti-diabetic, anti-arthritis and anti-inflammatory properties (Ojewole and Adewunmi, 2004). *Tetrapleura tetraptera* is used locally for the management of gastro-intestinal, cardiovascular, skin disorders, anaemia, diabetes, pains and as body cleanser (Kemigisha *et al.*, 2018). Akin-Idowu *et al.* (2011) demonstrated that the dry fruit of *Tetrapleura tetraptera* possesses micronutrient such as zinc and iron. It is used culinarily in the southeastern part of Nigeria (Odesanmi, *et al.*, 2009).

Phytochemical studies on the ethanol extracts of *Tetrapleura tetraptera* demonstrated the presence of tannin, flavonoids, saponins, alkaloids, terpenes, phenol, phlobatannin and steroids (Erukainure *et al.*, 2017). Phytochemicals are usually responsible for biological activities of plants (Aba and Asuzu, 2018). Flavonoids for instance possess tremendous antioxidant properties (Odesanmi *et al.*, 2009). Oxidative processes have been fingered in the pathogenesis of many diseases including hepatitis (Svegliati-Baroni *et al.*, 2001).

Acetaminophen overdose also precipitates hepatic disorders due to oxidative effects of N-acetyl-p-benzoquinone imine (NAPQI), a highly toxic intermediate product of acetaminophen hepatic metabolism (Vermeulen *et al.*, 1992). This toxic metabolite (NAPQI) under normal circumstance is made harmless by glutathione, a master antioxidant that is ubiquitous in the liver. However, following overdose, glutathione is overwhelmed and thus depleted giving room for the manifestation of the effects of NAPQI on the hepatocytes. Acetaminophen, an over-the counter analgesic and antipyretic drug, is one of the most abused drugs especially in the developing countries (Aba *et al.*, 2014).

There is a dearth of information on the studies of ethyl acetate pod extract of *Tetrapleura tetraptera* with regards to its effects on the liver. Ethyl acetate extracts have been documented to possess hepatoprotective properties by researchers (Panovska *et al.*, 2007). The main aim of this study was to investigate the possible ameliorative effects of the ethyl acetate pod extract of *Tetrapleura tetraptera* on acetaminophen-induced hepatotoxicity in rats.

Materials and Methods

Plant material

The pods of *Tetrapleura tetraptera* were purchased from a local market in Umuahia town, Abia state, Nigeria. They were identified by a botanist in the Department of Plant science and Biotechnology, University of Nigeria, Nsukka (Figure 1).



Figure 1. *Tetrapleura tetraptera* pods

Animals

Female albino Wistar rats weighing between 100-110 g were obtained from the Department of Veterinary Medicine, University of Nigeria, Nsukka. The rats were randomly assigned to groups and then acclimatized for two weeks prior to the commencement of the experiment. They were kept in a stainless wire mesh cage, provided with good clean water and fed *ad libitum* with Chikun Feed[®] (Finisher).

Experimental design

Thirty-five (35) female albino Wistar rats were assigned into seven groups (A-G) of five rats each. The rats were pretreated with distilled water, extract or silymarin as the case may be prior to intoxication with acetaminophen as shown in the Table 1.

Table 1. Treatment regimen for various groups

Group	Treatment
A	Treated with distilled water throughout the duration of the study (normal control)
B	Pretreated with distilled water + 2000 mg/kg acetaminophen (negative control)
C	Pretreated with 100 mg/kg <i>Tetraptera tetrapleura</i> + 2000 mg/kg acetaminophen
D	Pretreated with 200 mg/kg <i>Tetraptera tetrapleura</i> + 2000 mg/kg acetaminophen
E	Pretreated with 400 mg/kg <i>Tetraptera tetrapleura</i> + 2000 mg/kg acetaminophen
F	Treated with 200 mg/kg <i>Tetraptera tetrapleura</i> throughout the duration of study
G	Pretreated with 100 mg/kg Silymarin + 2000 mg/kg acetaminophen (standard control)

All treatments were through the oral route using gastric tube. The pretreatments lasted for 7 days. On the 8th day, 2000 mg/kg acetaminophen was administered. Forty-eight (48 h) post acetaminophen administration, blood samples were collected via the retrobulbar plexus in the eyes of the rats into a sample bottle devoid of anticoagulants and sera obtained for serum biochemical assays. Liver section was removed for histopathology assessment.

Preparation of plant extract

The pods of *Tetrapleura tetrapleura* were crushed into smaller pieces and then pulverized into powder. About 500 g of the pulverized pods were immersed in 2,500 litres of ethyl acetate in an air tight container. This mixture was shaken after every 2 h for 48 h, thereafter; it was filtered using No. 1 Whatman filter paper. The filtrate was concentrated following evaporation and stored in refrigerator.

Serum biochemical assays

Serum alanine aminotransferase (ALT) activity was determined by the Reitman-Frankel spectrophotometric method (Reitman and Frankel, 1957; Colville, 2002). Serum alanine aminotransferase catalyzes the reversible transamination of L-alanine and α -ketoglutarate to pyruvate and L-glutamate. The pyruvate is then reduced to lactate in the presence of lactate dehydrogenase (LDH) with the concurrent oxidation of NADH to NAD⁺. The system monitors the rate of change in absorbance at 340 nm over a fixed time interval. The rate of change in absorbance is directly proportional to the ALT activity in the sample.

The alkaline phosphatase (ALP) activity was determined by the phenolphthalein monophosphate method (Klein *et al.*, 1960; Colville, 2002). The alkaline phosphatase reacts with p-nitrophenyl phosphate to form p-nitrophenol. The rate of formation of this p-nitrophenol is directly proportional to the level of ALP activity. Both total and conjugated bilirubins were assayed according to Doumas *et al.* (1971). Direct bilirubin (conjugated) reacts with diazotized sulphanilic acid in alkaline medium to form a blue colored complex. Total bilirubin is determined in the presence of caffeine, which releases albumin bound to bilirubin by the reaction with diazotized sulphanilic acid. Superoxide dismutase (SOD) activity was assayed by the method of Kakkar

and Viswanathan (1984). The assay is based on the inhibition of the formation of NADH- phenazine methosulphate-nitroblue tetrazolium formazan. The activity of catalase was assayed by the method of Sinha (1972). Dichromate in acetic acid was reduced to chromic acetate, when heated in presence of hydrogen peroxide with the formation of per chromic acid as an unstable intermediate. The chromic acetate formed was measured at 590 nm. Catalase was allowed to split H_2O_2 for different periods of time. The reaction was stopped at different time intervals by the addition of dichromate acetic acid mixture and the remaining H_2O_2 was determined by measuring chromic acetate colorimetrically after heating the reaction mixture.

The reduced glutathione level was determined by the method of Beutler *et al.* (1963). This method was based on the development of yellow colour when 5,5'- dithio-bis-2-nitrobenzoic (DTNB) is added to compound containing sulphhydryl groups. The colour developed was read at 412 nm in spectrophotometer. The 2, 2-diphenyl-1- picrylhydrazyl (DPPH) photometric assay was determined by the method of Mensor *et al.* (2001). The DPPH is a stable purple colored compound which gets decolorized to yellow by antioxidants in the presence of methanol within 30 mins. The ferric reducing antioxidant power (FRAP) of the extract was assessed by the method of Benzie and Strain (1999). The assay quantifies the ability of the extract to reduce ferric (Fe^{3+}) to ferrous (Fe^{2+}) states. The histopathological studies of the liver tissues were done using the method of Drury *et al.* (1967).

Statistical analyses

Data obtained from this study were analyzed using One-way Analysis of Variance (ANOVA). Duncan's Multiple Range post hoc test was used to separate variant means. Probability values less than 0.05 were considered significant. The results were presented as Mean \pm Standard Error of the Mean.

Results

The results of the effects of ethyl acetate pod extract of *Tetraptera tetrapleura* on serum biochemical markers of liver damage in acetaminophen-induced hepatotoxicity in female albino rats is presented in Table 2. The mean alanine aminotransferase (ALT) activity of the rats administered acetaminophen (Group B) was significantly ($P<0.05$) higher than those of the other groups while the mean alkaline phosphatase (ALP) activities of groups B, C and D rats were significantly ($P<0.05$) higher than those of the groups A, E, F and G. The ALP activities of groups E, F and G were comparable but significantly ($P<0.05$) higher than that of the normal control group (group A). The mean direct bilirubin value of group B rats was significantly ($P<0.05$) lower than those of the other groups including that of the normal control group. The mean direct bilirubin value of group F rats was comparable to those of groups C, D and E but significantly higher than those of groups A, B and G. The mean total bilirubin levels of groups A and D rats were significantly lower than those of the groups B and G but comparable to those of groups C, E and F (Table 2).

Table 2. Effects of ethylacetate extract of *Tetraptera tetrapleura* on serum biochemical markers of liver damage in acetaminophen-induced hepatotoxicity in female albino rats

Parameter Group	ALT (iu/L)	ALP (iu/L)	DBIL (mg/dL)	TBIL (mg/dL)
A	39.66 ± 1.20 ^a	69.33 ± 3.17 ^{ab}	0.40 ± 0.01 ^b	0.89 ± 0.04 ^a
B	117.33 ± 11.25 ^b	114.66 ± 3.52 ^d	0.21 ± 0.04 ^a	1.21 ± 0.09 ^b
C	45.00 ± 3.21 ^a	104.00 ± 3.06 ^d	0.59 ± 0.05 ^{cd}	1.02 ± 0.04 ^{ab}
D	49.66 ± 2.72 ^a	105.00 ± 1.52 ^d	0.62 ± 0.05 ^{cd}	0.96 ± 0.05 ^a
E	44.00 ± 3.46 ^a	88.33 ± 4.40 ^c	0.60 ± 0.04 ^{cd}	1.04 ± 0.05 ^{ab}
F	51.66 ± 0.88 ^a	79.00 ± 4.51 ^{bc}	0.72 ± 0.04 ^d	1.07 ± 0.06 ^{ab}
G	39.67 ± 4.17 ^a	59.95 ± 5.66 ^c	0.54 ± 0.04 ^c	1.21 ± 0.09 ^b

Different letter superscripts along the same column indicate significant difference at $p < 0.05$.

ALT= Alanine aminotransferase; ALP= Alkaline phosphatase; DBIL= Direct bilirubin; TBIL= Total bilirubin

A=Normal control rats administered with distilled water @10ml/kg),

B= Negative control rats pretreated with distilled water for 7 days, then administered 2000 mg/kg acetaminophen

C= Rats group pretreated with 100 mg/kg of extract for 7 days then administered with 2000 mg/kg acetaminophen

D= Rats group pretreated with 200 mg/kg of extract for 7 days then administered with 2000 mg/kg acetaminophen

E= Rats group pretreated with 400 mg/kg of extract for 7 days then administered with 2000 mg/kg acetaminophen

F= Rats group treated with 200 mg/kg of extract alone without acetaminophen administration

G= Rats group pretreated with 100 mg/kg of Sylmarin for 7 days then administered with 2000 mg/kg acetaminophen

The results of *in vivo* antioxidant profile of acetaminophen-injured female albino rats pretreated with ethyl acetate pod extract of *Tetraptera tetrapleura* are presented in Table 3. Reduced glutathione levels of groups B and C were statistically similar ($P > 0.05$) to that of group A rats but significantly ($P < 0.05$) higher than those of groups D-G. The reduced glutathione value of group A rats was comparable to those of the groups D-G (Table 3). The catalase activities of groups A-C were significantly ($P < 0.05$) lower than those of the other groups while the catalase activity of group G rats was statistically higher ($P < 0.05$) than those of groups A-F. Groups E and F catalase activities were comparable but significantly ($P < 0.05$) higher than those of groups A-D (Table 3). The mean Superoxide dismutase activity of group B rats was significantly lower than those of groups C and F but comparable ($P > 0.05$) with those of groups A, D, E and G while the mean superoxide dismutase activity of group F rats was significantly ($P < 0.05$) higher than those of the other rat groups including group C rats (Table 3).

Table 3. *In vivo* antioxidant profile of acetaminophen-injured female albino rats pretreated with ethylacetate pod extract of *Tetraptera tetrapleura*

Parameter Group	Reduced glutathione (mg/dl)	Catalase (U/mg)	Superoxide dismutase (U/mg)
A	0.16 ± 0.01 ^{ab}	3.28 ± 0.33 ^a	11.48 ± 0.03 ^{ab}
B	0.08 ± 0.01 ^a	2.65 ± 0.12 ^a	11.19 ± 0.03 ^a
C	0.09 ± 0.02 ^a	3.11 ± 0.07 ^a	11.41 ± 0.12 ^b
D	0.20 ± 0.03 ^b	4.59 ± 0.24 ^b	11.49 ± 0.02 ^{ab}
E	0.20 ± 0.05 ^b	6.42 ± 0.72 ^c	11.49 ± 0.02 ^{ab}
F	0.20 ± 0.01 ^b	6.99 ± 0.06 ^c	11.49 ± 0.02 ^{ab}
G	0.24 ± 0.03 ^b	9.22 ± 0.35 ^d	11.44 ± 0.03 ^{ab}

Different letter superscripts along the same column indicate significant difference at $p < 0.05$.

A=Normal control rats administered with distilled water @10ml/kg)

B= Negative control rats pretreated with distilled water for 7 days, then administered 2000 mg/kg acetaminophen

C= Rats group pretreated with 100 mg/kg of extract for 7 days then administered with 2000 mg/kg acetaminophen

D= Rats group pretreated with 200 mg/kg of extract for 7 days then administered with 2000 mg/kg acetaminophen

E= Rats group pretreated with 400 mg/kg of extract for 7 days then administered with 2000 mg/kg acetaminophen

F= Rats group treated with 200 mg/kg of extract alone without acetaminophen administration

G= Rats group pretreated with 100 mg/kg of Sylmarin for 7 days then administered with 2000 mg/kg acetaminophen

Results of the *in vitro* antioxidant activity of ethyl acetate pod extract of *Tetrapleura tetraptera* and ascorbic acid using DPPH model are shown in Figure 2. The extract demonstrated concentration-dependent antioxidant activities with optimum activity of 86.62% at the concentration of 400 $\mu\text{g/ml}$ against 98.54% activity exhibited by the reference standard (ascorbic acid) at the same concentration of 400 $\mu\text{g/ml}$.

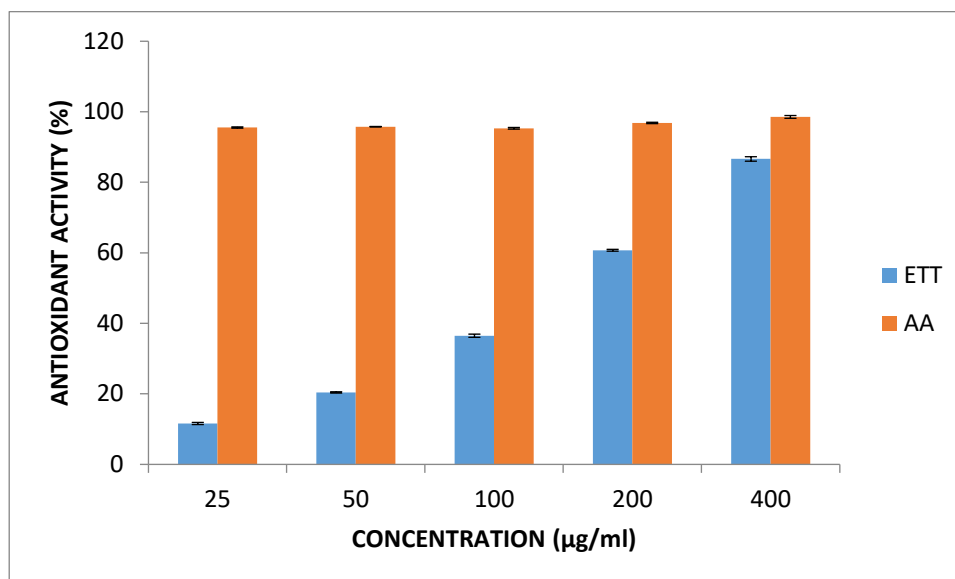


Figure 2. *In vitro* antioxidant activity of ethylacetate extract of *Tetrapleura tetraptera* pod and ascorbic acid using DPPH model

ETT= Ethyl acetate extract of *Tetrapleura tetraptera* pod; AA= Ascorbic Acid; DPPH= 2,2-diphenyl-1-picrylhydrazyl

Figure 3 shows the results of *in vitro* ferric reducing antioxidant power (FRAP) of the ethyl acetate extract of *Tetrapleura tetraptera* pod at varying concentration. The extract, at the concentrations of 25-200 $\mu\text{g/ml}$, did not exhibit any antioxidant activities (Figure 3). However, at 400 $\mu\text{g/ml}$, the extract showed 0.04 $\mu\text{mol/L}$ antioxidant activities as against 0.4 $\mu\text{mol/L}$ activity shown by ascorbic acid, the reference standard.

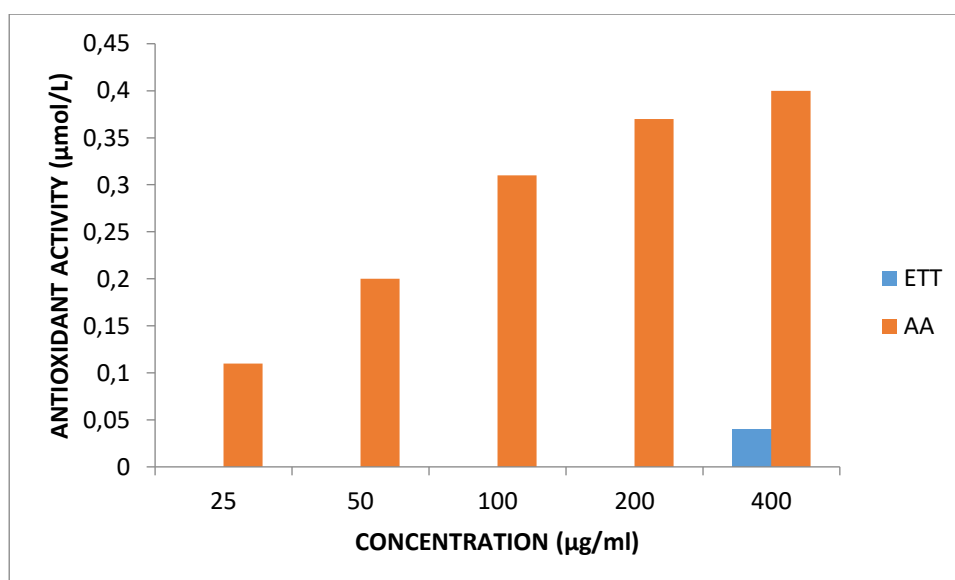


Figure 3. Ferric Reducing Antioxidant Power (FRAP) of ethylacetate extract of *Tetrapleura tetraptera* and ascorbic acid at varying concentrations

ETT= Ethyl acetate extract of *Tetrapleura tetraptera* pod; AA= Ascorbic Acid

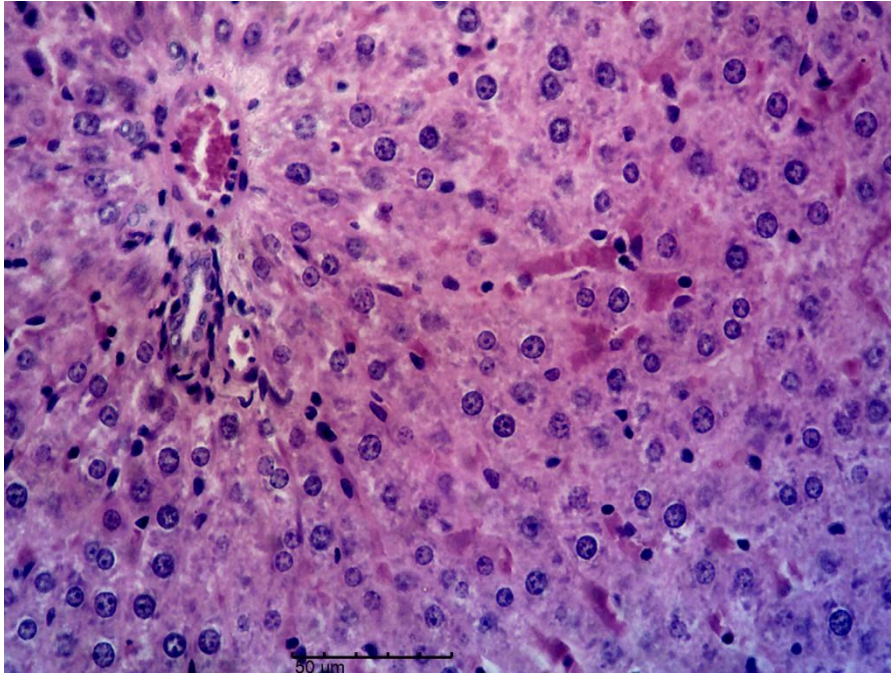


Figure 4. Photomicrograph of the liver of group A rats (Normal control) H&E, × 400

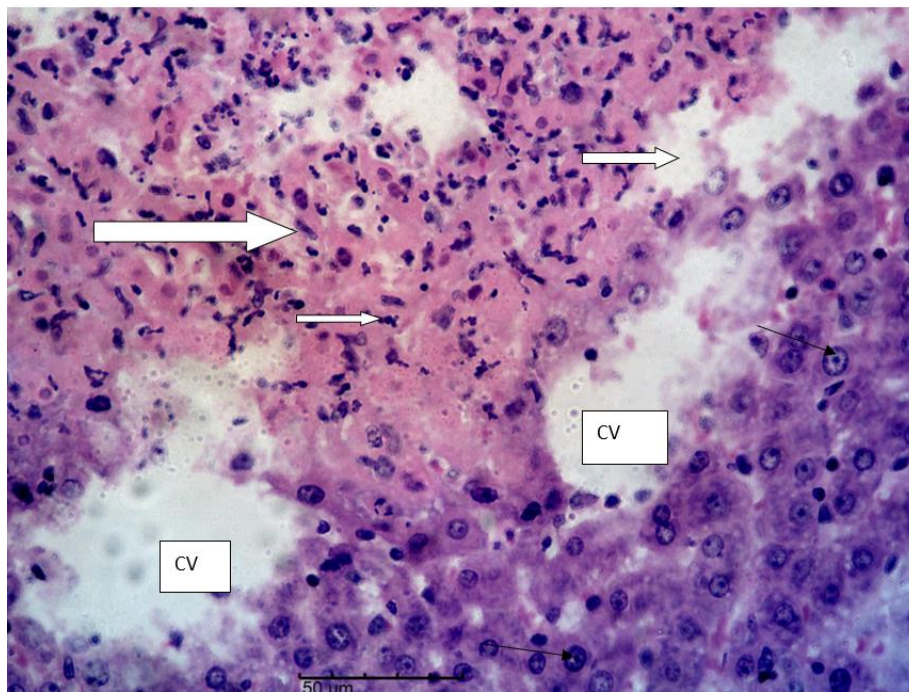


Figure 5. Photomicrograph of the liver of group B rats (intoxicated with 2000 mg/kg acetaminophen) showing severe diffuse hepatocellular necrosis and infiltration by the inflammatory cells (white arrows), central veins (CV) and few normal hepatocytes (black arrows). H&E, × 400

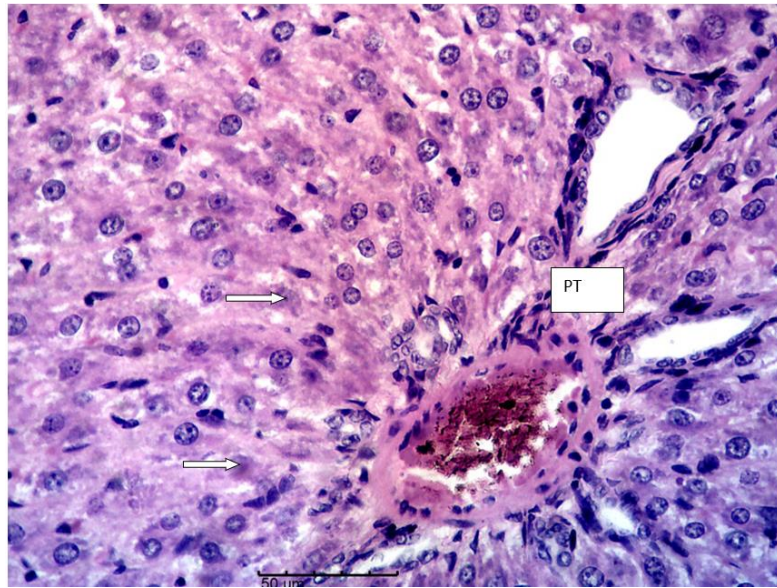


Figure 6. Photomicrograph of the liver of group C rats (pretreated with 100 mg/kg of ethyl acetate extract of *Tetrapleura tetraptera* pod for 7 days and intoxicated with 2000 mg/kg of acetaminophen) showing mild diffuse hepatocellular degeneration (arrows) and portal triad (PT). H&E, × 400

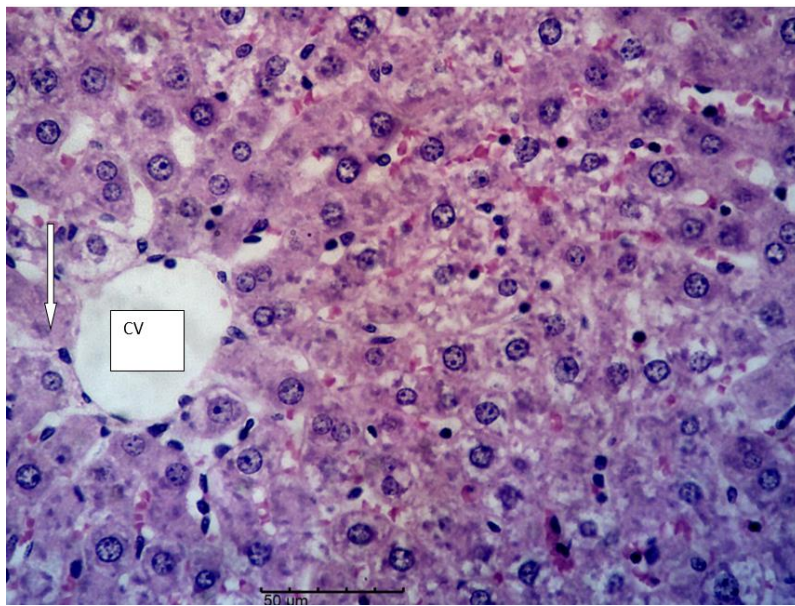


Figure 7. Photomicrograph of the liver of group D rats (pretreated with 200 mg/kg of ethyl acetate extract of *Tetrapleura tetraptera* pod for 7 days and intoxicated with 2000 mg/kg of acetaminophen) showing few degenerate hepatocytes (arrows) and central vein (CV). H&E, × 400

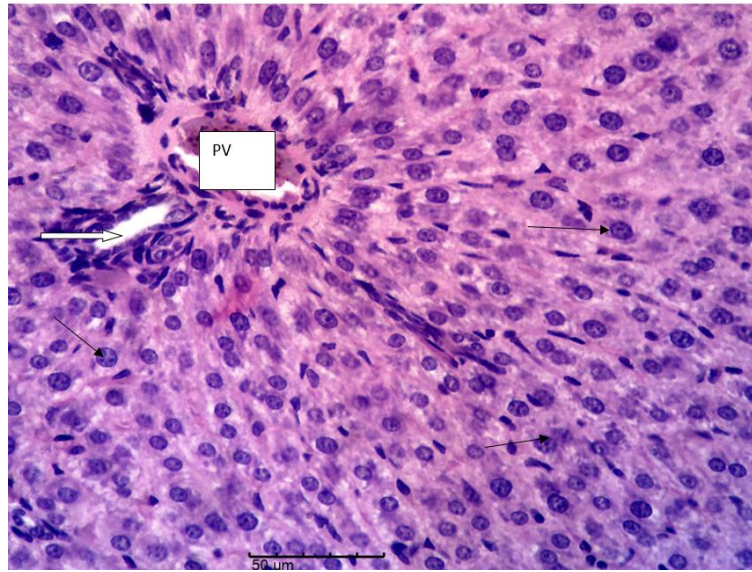


Figure 8. Photomicrograph of the liver of group E rats (pretreated with 400 mg/kg of ethyl acetate extract of *Tetrapleura tetraptera* pod for 7 days and intoxicated with 2000 mg/kg of acetaminophen) showing densely populated normal hepatocytes (black arrows), bile duct (white arrow) and portal vein (PV). H&E, $\times 400$

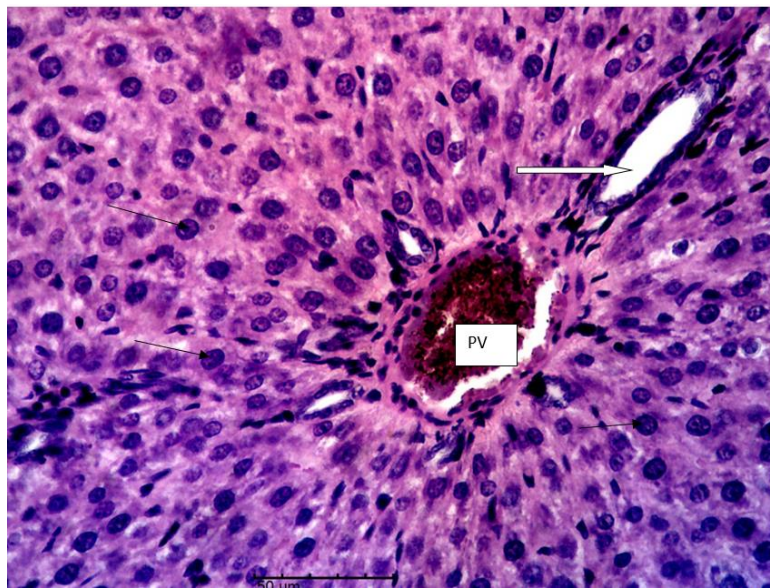


Figure 9. Photomicrograph of the liver of group F rats (treated with 200 mg/kg of ethyl acetate extract of *Tetrapleura tetraptera* pod alone) showing densely populated normal hepatocytes similar to that of the normal control (black arrows), bile duct (white arrow) and portal vein (PV). H&E, $\times 400$

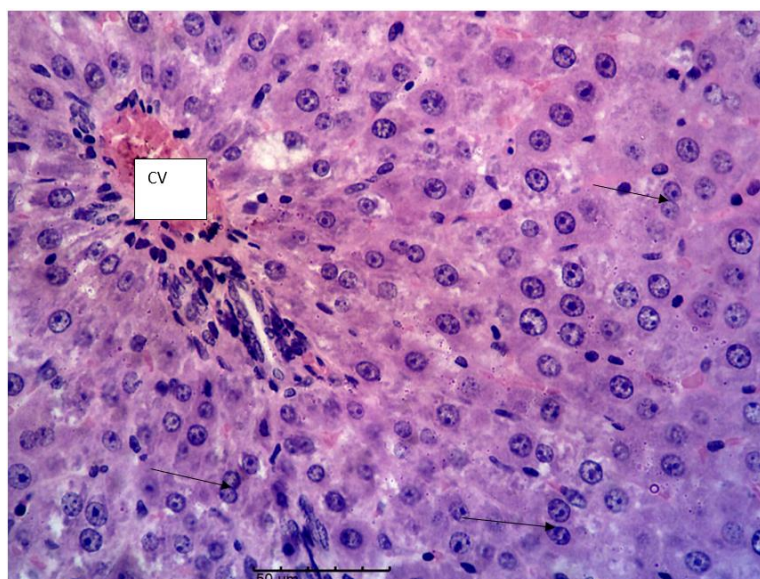


Figure 10. Photomicrograph of the liver of group G rats (pretreated with 100 mg/kg of silymarin for 7 days and intoxicated with 2000 mg/kg of acetaminophen) showing normal binucleate hepatocytes (black arrows) and central vein (CV). H&E, $\times 400$

Discussion

This study investigated the effects of ethyl acetate extract of *Tetrapleura tetraptera* pod on the liver damage markers of acetaminophen-induced hepatotoxicity in female rats.

The significantly higher activity of ALT in group B rats (group induced with 2000 mg/kg of acetaminophen alone) when compared to other groups (Table 2) implies that the hepatocytes of the group B rats were damaged. Researchers have noted that acetaminophen toxicity is capable of causing hepatocyte necrosis and increased serum ALT activity (Jarsiah *et al.*, 2019). The mean ALT activities in all the groups pretreated with the extract (C, D, E and F) were statistically comparable with the normal control (group A) and the standard control (group G). This probably suggests that pretreatment with the extract significantly ameliorated the damaging effect of acetaminophen on the hepatocytes. Johnkennedy *et al.* (2010) noted that ALT activity is a very good biochemical parameter for liver function test. Whenever there is injury or necrosis of the hepatocytes, enzymes (such as ALT) that are resident in the hepatocytes ooze out into the extracellular fluid (Gill *et al.*, 2014).

Similarly, the significant elevations in the serum ALP activities in groups B, C and D (Table 2) indicate liver damage of hepatobiliary origin as noted by Burtis and Ashwood (1999). Alkaline phosphatase, a dephosphorylating enzyme is ubiquitous in the liver particularly in the biliary epithelium. It therefore implies that injury to the cells lining the endothelium of the biliary ducts certainly will cause a rise in the ALP activity. Acetaminophen has been documented to cause increased serum activities of ALP (Aba *et al.*, 2014). Increase in the mean ALP activity of group B rats (intoxicated with 2000 mg/kg of acetaminophen only) is not unrelated with acetaminophen administration. Increased ALP activities in the groups pretreated with lower doses of the extract (groups C and D) when compared to the group pretreated with the higher dose of the extract (Table 2) (group E) indicates that the highest dose of the extract offered a better hepatobiliary protection compared to the lower doses.

Bilirubin is a byproduct of red blood cell metabolism. Unconjugated bilirubin is taken to the liver for conjugation into direct bilirubin. Both unconjugated and direct bilirubin make up total bilirubin. In the cases of injury to the liver, total bilirubin increases due to increases in unconjugated bilirubin occasioned by inability

of the liver to perform its conjugation function (Boris *et al.*, 2001). On the other hand, elevated direct bilirubin may be a consequence of post hepatic pathology such as biliary obstruction (Feverly, 2008). In this study, the elevated level of total bilirubin values in the groups intoxicated with acetaminophen compared to the normal control group most probably indicates damage to the hepatocytes (Table 2). It appears the extract were not able to facilitate bilirubin excretion.

Significantly decreased value of mean reduced glutathione (GSH) in group B rats (intoxicated with acetaminophen alone) (Table 3) corroborates the submission by Sun *et al.* (2002) that NAPQI, a toxic metabolite of acetaminophen depletes hepatic GSH. However, the groups that were pretreated with higher doses of the extract (groups D and E) prior to acetaminophen intoxication showed significantly higher values of GSH when compared with the group that was not pretreated (group B). This indicates that the extract, at higher doses, either increased GSH production or prevented acetaminophen metabolite from depleting GSH. The GSH is a master antioxidant saddled with the responsibility of guarding the cells from oxidative damages by scavenging reactive oxygen species and nitrogen radicals (Yuan *et al.*, 2009).

The catalase activities of the rats pretreated with the extract especially at the higher doses were significantly higher than that of the negative control (Table 3) (group B) indicating the ability of the extract to increase antioxidant activity of the system. Sundaram *et al.* (2014) noted that catalase protects organ damage by decomposing hydrogen peroxide (a potent radical) to water and oxygen.

Superoxide dismutase (SOD), on the other hand, catalyzes the dismutation of a free radical, superoxide anion. When SOD is deficient, the superoxide reacts with nitric oxide to produce peroxynitrite which is a potent oxidant and a nitrosating agent capable of causing damages to DNA, lipids and protein (Pacher *et al.*, 2007). In the present study, the SOD activity was highest in the group administered the extract alone without acetaminophen intoxication compared to every other group (Table 3). This probably implies that the extract on its own, is capable of boosting SOD activity.

Assessment of the *in vitro* antioxidant activities of the plant extract using DPPH and FRAP indicated that the extract possesses antioxidant properties which was seen to be concentration-dependent in DPPH model (Figure 2). The FRAP model only detected antioxidant activity of the extract at 400 µg/ml (Figure 3). The DPPH assess the ability of the extract to scavenge free radicals while FRAP measures power of the extract to reduce ferric (Fe^{3+}) to ferrous (Fe^{2+}) states (Mensor *et al.*, 2001; Benzie and Strain 1999). The DPPH model appears to be more sensitive than the FRAP model.

Photomicrographic representations of group B rats (intoxicated with 2000 mg/kg acetaminophen only) showed diffuse hepatocellular necrosis with massive infiltration of inflammatory cells (Figure 5). This finding is in agreement with the studies of Laskin (1992) who also reported hepatocellular necrosis following acetaminophen intoxication. The liver histomorphology of rats in groups A (Normal control) is similar to that of the group that received the extract alone (group F) and to that of the rats that received silymarin as pretreatment (group G). They show normal hepatic cells with well-defined cytoplasm, prominent nucleus and central vein which are features consistent with normal hepatocytes (Jane *et al.*, 2014). Mild hepatocytes degenerations were seen in the rats pretreated with lower doses of the extract (groups C and D) while the group pretreated with the highest dose of the extract (group E) showed normal histomorphological architecture (Figures 4-10). The finding indicates that the extract, at highest dose of 400 mg/kg pretreatment offered significant hepatoprotective ability against acetaminophen injury.

Conclusions

The ethyl acetate extract of *Tetrapleura tetraptera* pod possesses hepatoprotective potentials. The extract also demonstrated both *in vivo* and *in vitro* antioxidant activities. Both hepatoprotective effects and antioxidant activities of the extract were dose and concentration dependent respectively.

Authors' Contributions

SCU: conceptualized, designed and supervised the work. MAK: carried out the experiment and collected data. PEA: analysed and drafted the manuscript.

All authors read and approved the final manuscript.

Ethical approval (for researches involving animals or humans)

The handling, housing and welfare of the laboratory animals were in accordance with ethical rules and regulations guiding the conduct of research as approved by the University of Nigeria, Nsukka Ethical Committee on the use of research animals.

Acknowledgements

This research received no specific grant from any funding agency in the public, commercial, or not-for-profit sectors.

Conflict of Interests

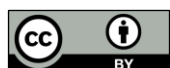The authors declare that there are no conflicts of interest related to this article.

References

- Aba PE Ozioko IE, Udem ND, Udem SC (2014). Some biochemical and haematological changes in rats pretreated with aqueous stem bark extract of *Lophira Lanceolata* and intoxicated with paracetamol (Acetaminophen). Journal of Complementary and Integrative Medicine 11(4):273-277. <https://doi.org/10.1515/jcim-2014-0007>
- Aba PE, Asuzu IU (2018). Mechanisms of actions of some bioactive anti-diabetic principles from phytochemicals of medicinal plants: A review. Indian Journal of Natural Products and Resources 9(2):85-96.
- Adesina SK, Iwalewa EO, Johnny II (2016). *Tetrapleura tetraptera* Taub ethnopharmacology, chemistry, medicinal and nutritional values-a review. British Journal of Pharmaceutical Research 12:1-22. <https://doi.org/10.9734/BJPR/2016/26554>
- Akin-Idowu PE, Ibitoye DO, Ademoyegun OT, Adeniyi OT (2011). Chemical composition of the dry fruit of *Tetrapleura tetraptera* and its potential impact on human health. Journal of Herbs Spices and Medicinal Plants 17(1):52-61. <https://doi.org/10.1080/10496475.2011.560087>
- Benzie FF, Strain JJ (1999). Ferric reducing/Antioxidant power assay: Direct measure of total antioxidant activity of biological fluids and modified version for simultaneous measurement of total antioxidant power and ascorbic acid concentration. Methods in Enzymology 299:15-23. [https://doi.org/10.1016/s0076-6879\(99\)99005-5](https://doi.org/10.1016/s0076-6879(99)99005-5)

- Beutler E, Duron O, Kelly BM (1963). Improved method for determination of blood glutathione. *Journal of Laboratory and Clinical Medicine* 61:882-888.
- Blay DJ (1997). The distribution and ecological requirements for the growth of *Tetrapleura tetra-ptera*. *Ghana Journal of Forestry* 5:40-50.
- Boris R, Kuster H, Ugele B, Gruber R, Horn K (2001). Total bilirubin measurement by photometry on a blood gas analyzer: potential for use in neonatal testing at the point of care. *Clinical Chemistry* 47(10):1845-1847. <https://doi.org/10.1093/clinchem/47.10.1845>
- Burtis CA, Ashwood ER (1999). *Tietz textbook of clinical chemistry*. Saunders, 3rd edition, pp 336-356.
- Colville J (2002). Blood chemistry. In: Hendrix CM (Ed). *Laboratory Procedures for Veterinary Technicians*. 4th edn. Mosby, St. Louis, pp 75-103.
- Doumas BT, Perry BW, Sasse EA, Straumfjord Jr JV (1971) Standardization in bilirubin assays: evaluation of selection methods and stability of bilirubin solutions. *Clinical Chemistry* 19:984-993.
- Drury RA, Wallington A, Cameroun SR (1967). *Carleton's Histological Techniques*. Oxford University Press, New York, pp 1-420.
- Erukainure OL, Onifade OF Odjobo B, Olaschinde T, Adesioye T Tugbobo-Amisu O, ... Okonrokwo I (2017) Ethanol extract of *Tetrapleura tetraptera* fruit peels: Chemical characterization, and antioxidant potentials against free radicals and lipid peroxidation in hepatic tissues. *Journal of Taibah University for Science* 11(6):861-867. <https://doi.org/10.1016/j.jtusc.2017.03.007>
- Feverly J (2008). Bilirubin in clinical practice: A review. *Liver International* 28:592. <https://doi.org/10.1111/j.1478-3231.2008.01716.x>
- Gill KK, Sandhu HS, Kaur K (2014). Evaluation of biochemical alterations produced by combined exposure of fenvalerate and nitrate in *Bulbalus bubalis*. *Veterinary World* 7(3):146-151.
- Jane TN, Matthias OA, Ikechukwu FU (2014). Antioxidant and hepatoprotective activity of fruit extract of *Tetrapleura tetraptera*. *Jordan Journal of Biological Sciences* 7(4):251-255.
- Johnkennedy N, Adamma E, Austin A, Chukwunyer N (2010). Alterations on biochemical parameters of wister rats administered with sulfadoxine and pyromethamine (Fansidar®). *AI Ameen Journal of Medical Sciences* 3(4):317-321.
- Kakkar SB, Viswanathan P (1984). A modified spectrophotometric assay of superoxide dismutase. *Indian Journal of Biochemistry and Biophysics* 21:130-132.
- Jarsiah P, Karami M, Nosrati A, Alizadeh A, Hashemi-Soteh MB (2019). Circulating miR-122 and miR-192 as specific and sensitive biomarkers for drug-induced liver injury with acetaminophen in rats. *Jundishapur Journal of Natural Pharmaceutical Products* 14(2):e65678. <https://doi.org/10.5812/jjnpp.65678>
- Kemigisha E, Owusu EO, Elusiyan CA, Omujal F, Tweheyo M Bosu PP (2018). *Tetrapleura tetraptera* in Ghana, Nigeria and Uganda: house hold uses and local markets. *Forests, Trees and Livelihoods*. <https://doi.org/10.1080/14728028.2018.1498027>
- Klein B, Read PA, Babson AL (1960). Rapid method for the quantitative determination of serum alkaline phosphatase. *Clinical Chemistry* 6:269-275.
- Laskin DL (1992). Role of macrophages and endothelial cells in hepatotoxicity. In: Billiar TR, Curran RD (Eds). *Hepatocyte and Kupffer Cells Interactions*. CRC Press, Boca Raton, Florida, pp 147-168.
- Mensor F, Luciana L, Fabia S, Menezes G, Leitao AS, Reis TC, ... Leitao G (2001). Screening of Brazilian plant extracts for antioxidant activity by the use of DPPH free radical method. *Phytotherapy Research* 15:127-130. <https://doi.org/10.1002/ptr.687>
- Odesanmi SO, Lawal RA, Ojokuku SA (2009). Effects of ethanolic extract of *Tetrapleura tetraptera* on liver function profile and histopathology in male Dutch white rabbits. *International Journal of Tropical Medicine* 4(4):136-139.
- Ojewole JAO, Adewunmi CO (2004). Anti-inflammatory and hypoglycaemic effects of *Tetrapleura tetraptera* (Taub) [Fabaceae] fruit aqueous extract in rats. *Journal of Ethnopharmacology* 95(2-3):177-182. <https://doi.org/10.1016/j.jep.2004.06.026>
- Okwu DE (2003). The potential of *Ocimum gratissimum*, *Pergularia extensa* and *Tetrapleura tetraptera* as spices and flavouring agents. *Nigerian Agriculture Journal* 35:143-148.
- Pacher P, Beckman JS, Liaudet L (2007). Nitric oxide and peroxynitrite in health and disease. *Physiological Reviews* 7:315-424. <https://doi.org/10.1152/physrev.00029.2006>

- Panovska TK, Kulevanova S, Gjorgoski I, Bogdanova M, Petrushevska G (2007). Hepatoprotective effect of the ethyl acetate extract of *Teucrium polium* L. against carbon tetrachloride-induced hepatic injury in rats. *Acta Pharmaceutica* 57(2):241-248. <https://doi.org/10.2478/v10007-007-0020-x>
- Reitman S, Frankel S (1957). A colorimetric method for determination of serum glutamic oxaloacetic and glutamic pyruvic transaminase. *American Journal of Clinical Pathology* 28:56-62. <https://doi.org/10.1093/ajcp/28.1.56>
- Sinha AK (1972) Colorimetric assay of catalase. *Analytical Biochemistry* 47(2):389-394. [https://doi.org/10.1016/0003-2697\(72\)90132-7](https://doi.org/10.1016/0003-2697(72)90132-7)
- Sun, YM, Zhang HY, Chen DZ, Liu CB (2002). Theoretical elucidation on the antioxidant mechanism of curcumin: a DFT study. *Organic Letters* 4:2909-2911. <https://doi.org/10.1021/ol0262789>
- Sundaram NS, Hemshekhar M, Thushara RM, Santhosh MS, Kumar SK, Paul M, ... Girish KS (2014). Tamarind seed extract mitigates the liver oxidative stress in arthritic rats. *Food and Function* 5:587-597. <https://doi.org/10.1039/c3fo60381d>
- Svegliati-Baroni G, Saccomanno S, van *Goor H*, Jansen P, Benedetti A, Svegliati-Baroni G, Moshage H (2001) Involvement of reactive oxygen species and nitric radicals in activation and proliferation of rat hepatic stellate cells. *Liver* 21:1-12. <https://doi.org/10.1034/j.1600-0676.2001.210101.x>
- Vermeulen NP, Bessems JG, Van de Streat R (1992). Molecular aspects of paracetamol-induced hepatotoxicity and its mechanism-based prevention. *Drug Metabolism Review* 24:13. <https://doi.org/10.3109/03602539208996298>
- Yuan L, Kaplowitz N (2008). Glutathione in liver diseases and hepatotoxicity. *Molecular Aspects of Medicine* 30(1-2):29-41. <https://doi.org/10.1016/j.mam.2008.08.003>



The journal offers free, immediate, and unrestricted access to peer-reviewed research and scholarly work. Users are allowed to read, download, copy, distribute, print, search, or link to the full texts of the articles, or use them for any other lawful purpose, without asking prior permission from the publisher or the author.

License - Articles published in *Notulae Scientia Biologicae* are Open-Access, distributed under the terms and conditions of the Creative Commons Attribution (CC BY 4.0) License.

© Articles by the authors; SHST, Cluj-Napoca, Romania. The journal allows the author(s) to hold the copyright/to retain publishing rights without restriction.