

Anti-ulcer property of methanol fraction of *Callichilia subsessilis* leaf extract in albino rats

Samuel O. ONOJA^{1*}, Gladys C. EZE², Nkeiruka E. UDEH¹,
Chinyere B. C. IKPA³, Daniel UGOJI¹, Jessica I. UKWUEZE¹,
Kelechi G. MADUBUIKE¹, Patrick E. ABA⁴, Maxwell I. EZEJA¹

¹Michael Okpara University of Agriculture, Department of Veterinary Physiology and Pharmacology, Umudike, PMB 7267, Abia State, Nigeria; onoja.samuel@mouau.edu.ng (*corresponding author); samonreal@yahoo.com; ukwueze.ifunanya@mouau.edu.ng; udeh.nkeiruka@mouau.edu.ng; danny.ugoji@gmail.com; madubuike.kelechi@mouau.edu.ng; maxwell.ezeja@gmail.com

²Alex Ekwueme Federal University, Department of Agriculture, Ndufu Alike-Ikwo, Ebonyi State, Nigeria; joanezech1@gmail.com

³Imo State University, Department of Chemistry, P.M.B 2000, Owerri, Imo State, Nigeria; ikpacbc@gmail.com

⁴University of Nigeria, Department of Veterinary Physiology and Pharmacology, Nsukka, Nigeria; patrick.aba@unn.edu.ng

Abstract

Peptic ulcer is one of the major causes of morbidity and mortality worldwide. It is treated with herbal preparations in developing countries. This study investigated the anti-ulcer property of methanol fraction of *Callichilia subsessilis* leaf in albino rats. Methanol extract prepared through the cold maceration method was partitioned into chloroform and methanol fraction using a separating funnel. The methanol fraction of *Callichilia subsessilis* (MFCS) was concentrated *in vacuo* using a rotary evaporator. The acute toxicity was determined using the brine shrimp lethality test and the up-and-down method at a dose limit of 2000 mg/kg. The anti-ulcer activity of MFCS was evaluated at the doses of 12.5, 25 and 50 mg/kg using indomethacin- and ethanol-induced ulcer models. Misoprostol was used as a reference standard. The ulcer score, index and severity were determined using standard methods. Isolated rabbit jejunum tissue in Tyrode's solution was used to establish the possible mechanism of anti-ulcer activity of MFCS. The LC₅₀ and LD₅₀ of MFCS were greater than 10,000 ppm and 2,000 mg/kg respectively. The MFCS exhibited significant ($p < 0.05$) dose-dependent anti-ulcer activity in all the ulcer models used. The MFCS (25 mg/kg) produced 52% and 41.33% inhibition of ulcer index in the indomethacin- and ethanol-induced ulcer models respectively. In the isolated tissue model, MFCS caused significant ($p < 0.05$) relaxation of the rhythmic contraction of the isolated rabbit jejunum and partially inhibited acetylcholine- and histamine-induced contraction of the jejunal smooth muscles. In conclusion, MFCS exhibited anti-ulcer (antihistaminic and anticholinergic) effects. This study justified the use of *Callichilia subsessilis* leaves in traditional medicine as an anti-ulcer remedy.

Keywords: anticholinergic receptor; antihistamine; anti-ulcer; *Callichilia subsessilis*; ethanol; indomethacin

Introduction

Peptic ulcer is referred to as a peptic injury of the digestive tract and occurs mainly in the stomach or upper duodenum, but can also be found in the lower esophagus and Meckel's diverticulum (Albaqawi *et al.*, 2017; Lanan and Chan, 2017; Sayehmiri *et al.*, 2018). It is a break in the mucosal lining of the gastrointestinal tract. The global prevalence is estimated at 4-15% and an annual incidence rate of 0.1-0.3% (Lanan and Chan, 2017; Sayehmiri *et al.*, 2018). It is caused by an imbalance in the defensive and offensive factors of the gastrointestinal mucosa integrity (Sayehmiri *et al.*, 2018). The defensive factors are mucus, bicarbonate, blood fluids, prostaglandins and antioxidants, while the offensive factors are excessive gastric acid, *Helicobacter pylori* and free radicals. The common causes of peptic ulcer are *H. pylori* and indiscriminate use of non-steroidal anti-inflammatory drugs. Some of the predisposing factors are cigarette smoking, Behcet's disease, Zollinger-Ellison syndrome, Crohn's disease and stress (Albaqawi *et al.*, 2017). Some of the associated complications of peptic ulcer are gastric bleeding (which occur in 15% of patients), perforation and obstruction. The clinical management of peptic ulcer involves the use of drugs like antacids, proton pump inhibitors, histamine (H₂) receptor antagonists, cytoprotective agents and antibiotics (Paguigan *et al.*, 2014). Peptic ulcer is more effectively treated with multiple drug combinations. One of the commonly used combinations is a proton pump inhibitor plus amoxicillin plus clarithromycin with or without a cytoprotective agent (bismuth or misoprostol) (Fallone *et al.*, 2016; Lanan and Chan, 2017). There is a growing interest in the use of herbal preparation in the management of peptic ulcer and other diseases (Balan *et al.*, 2014; Zabidi *et al.*, 2012). World Health Organization (WHO) estimated that 80% of the world population depend on herbal medicine for their primary healthcare needs (Raskin *et al.*, 2002). The increasing use of herbal preparation in ulcer management is attributed to the resistance of *H. pylori* to most antibiotics and other factors such as; unavailability, high cost, and side effects of orthodox medicines (Malferteiner *et al.*, 2017). One of the commonly used plants in herbal medicine preparation is *Callichilia subsessilis*.

Callichilia subsessilis (Benth.) Stapf belongs to the family *Apocynaceae*. It is known as "Aba-nua" in Ghana, "Vaimi" in Sierra Leone and "Mkpiri" in Igboland Nigeria (Burkill, 1985). The habitat is along the coast of West Africa. The infusion or decoction of the leaves is used by traditional bone setters for fracture reduction in Ozuitem, in Abia State, Nigeria. Preliminary investigation of phytochemical constituents has revealed the presence of alkaloids, saponins, flavonoids, terpenes, glycosides and tannins in the methanol extract of *C. subsessilis* leaf (Onoja *et al.*, 2018). The anti-inflammatory, analgesic and antioxidant potential of *C. subsessilis* have also been documented (Onoja *et al.*, 2018). The leaves of *C. subsessilis* are added in herbal infusions and/or poultice used in ulcer treatment in Southeast Nigeria (oral communication). Despite the use of *C. subsessilis* in the traditional treatment of ulcer, to the best of our knowledge, there is a dearth of information in the scientific literature on its anti-ulcer potential. Therefore, this study investigated the anti-ulcer activity of methanol fraction *Callichilia subsessilis* leaf extract in Wistar rats.

Materials and Methods

Collection and authentication of plant material

Fresh leaves of *C. subsessilis* were collected and authenticated by Mr. Ndukwe Ibeh, a taxonomist with the College of Natural Resources and Environmental Management, Michael Okpara University of Agriculture, Umudike, Nigeria. Voucher sample (MOUAU/VPP/2016/20) was deposited in the Department of Veterinary Physiology and Pharmacology of same University.

Preparation of the plant extract

The leaves were washed and sorted for any contaminant and dried under shed (on laboratory bench) before grinding into a coarse powder with a manual blender. The coarse powder was weighed with a balance

scale, then soaked in 80% methanol in aqueous methanol in a Winchester bottle at room temperature for 48 h following vigorous shaken every 3 h. Filtration was done using Whatman No 1 filter paper and the filtrate was concentrated in a hot air oven set at 40 °C.

Solvent-solvent partitioning

The methanol extract of *C. subsessilis* was partitioned into methanol and chloroform fractions using a separating funnel. The two partitions/fractions were evaporated to dryness using a hot air oven. The methanol fraction of *C. subsessilis* (MFCS) was used for the study and it was stored in a refrigerator at 4 °C throughout the experiment.

Brine shrimp lethality test

The eggs of brine shrimp were collected and hatched using seawater in a small beaker after 24 h. The active and swimming nymphs were counted with the aid of a glass capillary dropper into test tubes at 10 active larvae per test tube. The nymphs in seawater were incubated with varied concentrations of MFCS (625, 1250, 2500, 5000 and 10000 ppm) in triplicates for 24 hours at room temperature. After 24 hours of incubation, the surviving nymphs were counted and the percentage mortality was calculated as follows:

$$\text{Percentage mortality} = \frac{\text{initial number of viable nymph} - \text{final number of viable nymph}}{\text{initial number of viable nymph}} \times \frac{100}{1}$$

Experimental animals

Sixty albino Wistar rats (weighing average 110 g) of both sexes and a rabbit obtained from the laboratory animal unit of the Department of Veterinary Physiology and Pharmacology, Michael Okpara University of Agriculture, Umudike were used in this work. The animals were acclimatized for two weeks, under standard conditions. They were housed in aluminum cages and fed with standard commercial pelleted feed (Vital feed, Nigeria) and clean drinking water was provided *ad-libitum*. The experimental protocol was approved by the Institutional Animal Ethics Committee of the College of Veterinary Medicine, Michael Okpara University of Agriculture Umudike (MOUAU/CVM/REC/18025).

Acute toxicity test

The up-and-down procedure with a dose limit of 2000 mg/kg was adopted (OECD, 2008). Ten (10) rats were used for the study as described by Onoja *et al.* (2018).

Indomethacin-induced ulcer model

The effect of the MFCS on the indomethacin-induced ulcer model was studied according to the method of Ubaka *et al.* (2010). Twenty-five rats were assigned to five groups (A-E; n = 5). Groups A and B served as negative and positive control and received distilled water 5 ml/kg and misoprostol 50 µg/kg body weight (BW), respectively. Groups C-E received MFCS 12.5, 25 and 50 mg/kg BM, respectively. The distilled water, misoprostol and MFCS were administered orally. One (1) hour post-treatment, all the rats were given indomethacin (20 mg/kg BW) *per os*. Four hours later, all the rats were sacrificed by cervical dislocation. The stomachs were removed, ligated at both ends, inflated with 1% formalin and later submerged in 1% formalin for 24 h. Thereafter, the stomachs were cut open along the greater curvature to view and score the ulcer lesion under the hand lens. The ulcers were scored as follows: 0 = no ulcer, 1 = superficial ulcer, 2 = deep ulcer and 3 = perforation. The ulcer index and percentage inhibition were calculated.

$$\text{Ulcer Index (UI)} = \frac{(\text{Un} + \text{Us} + \text{Up})}{10}$$

Where: UI= ulcer index, Un = average number of ulcers per rat, Us = average severity score, Up = percentage of the animal with ulcer.

$$\text{Percentage (\%) ulcer inhibition} = \frac{\text{UI (control)} - \text{UI (treatment)}}{\text{UI (control)}} \times \frac{100}{1}$$

Ethanol-induced ulcer

The effect of the MFCS on the ethanol-induced ulcer model was studied according to the method of Ubaka *et al.* (2010). Twenty-five rats were assigned to five groups (A-E; n = 5). Groups A and B served as negative and positive control and received distilled water 5 ml/kg and misoprostol 50 µg/kg BW, respectively. Groups C-E received MFCS 12.5, 25 and 50 mg/kg BW, respectively. The distilled water, misoprostol and MFCS were administered orally. One (1) hour post-treatment, all rats were given indomethacin (20 mg/kg BW) *per os*. Four hours later, all the rats were sacrificed for cervical dislocation. The stomachs were processed and ulcer score, ulcer index and percentage inhibition were determined as described above.

Isolated rabbit jejunum tissue model

An adult rabbit was sacrificed (by stunning) after 24 h fast. A segment of the jejunum (about 3 cm long) was cut out from the remaining length of the organ and the adhering mesentery was trimmed off. The tissue was then suspended in a 35 ml organ bath containing Tyrode's solution (NaCl 8.00gl⁻¹, KCl 0.02gl⁻¹, CaCl₂ 0.20gl⁻¹, NaHCO₃ 1.00gl⁻¹, NaH₂PO₄ 1.00gl⁻¹, MgCl₂ 0.10 gl⁻¹, glucose 2.00gl⁻¹, MgSO₄·7H₂O 2.0gl⁻¹) with the lower end of the tissue segment tied to the bottom of the organ bath chamber and the other end tied to a transducer. The set up was maintained at 37 °C and aerated with air. The effect of acetylcholine and MFCS were tested on the strips of rabbit jejunum both before and after antagonizing their cholinergic and histaminic receptors. Digital physiography was used to record the pre- and post-treatment contraction of the suspended jejunum segment.

$$\text{Final bath concentration (FBC)} = \frac{U \times C}{V}$$

Where: U =volume added, C =concentration of extract/drug, V =volume of organ bath

Histopathological examination

The stomach tissues of rats of indomethacin-induced ulcer models were fixed in 10% formal saline, processed using a standard protocol, sectioned and stained with hematoxylin and eosin (H & E) stained. The photomicrographs of the stomach tissues were captured *under a digital/light microscope*.

Statistical analysis

Data generated were presented as mean ± SEM and analyzed using one-way-analysis of variance (ANOVA) and post-hoc comparisons were done using KruskalWallis test on SPSS version 22. Values of *P* < 0.05 were considered significant.

Results*Brine shrimp lethality test*

The MFCS at 10,000 ppm caused 30% mortality of the nymph. The LC₅₀ of the MFCS was greater than 10,000 ppm (Figure 1).

Acute oral toxicity test

The MFCS elicited neither signs of toxicity nor mortality in the treated rats at 2000 mg/kg. The LD₅₀ of the MFCS was thus greater than 2000 mg/kg.

Effects of MFCS against indomethacin-induced gastric ulcer

The MFCS and misoprostol elicited significant (*p* < 0.05) reductions in ulcer numbers, scores and index in the treated rats relative to the distilled water treated rats. The MFCS produced dose-dependent effects up to 25 mg/kg body weight. The optimum effect of the MFCS was exhibited at 25 mg/kg (Table 1).

Effects of MFCS against ethanol-induced gastric ulcer

The MFCS and misoprostol caused a significant ($p < 0.05$) decrease in the ulcer index of the treated rats compared to the distilled water treated group. The gastroprotective effects of the MFCS were comparable to the effect of misoprostol (Table 2).

Gross morphology of stomach of indomethacin-induced gastric ulcer in rats

The gross morphology of the stomach of the indomethacin-induced gastric ulcer is shown in Figure 2. The letter ‘U’ denotes the area of ulceration. The distilled water treated rats (Figure 2A) had more area of ulceration relative to other treatment groups. The MFCS (25 mg/kg) treated group (Figure 2D) had no ulcer lesion.

Table 1. Effects of MFCS against indomethacin-induced gastric ulcer

Treatment	Ulcer number	Ulcer score	Ulcer index	% inhibition
Distilled water 5 ml/kg	21.40 ± 7.93	28.60 ± 11.16	13.00 ± 1.90	-
Misoprostol 50 µg/kg	8.00 ± 5.41*	10.00 ± 5.92*	7.80 ± 1.12*	40
MFCS 12.5 mg/kg	6.75 ± 5.15*	7.25 ± 5.64*	7.02 ± 0.82*	46
MFCS 25 mg/kg	1.20 ± 0.58*	1.20 ± 0.58*	6.24 ± 0.11*	52
MFCS 50 mg/kg	4.20 ± 1.98*	4.20 ± 1.98*	8.84 ± 0.39*	32

*P < 0.05 when compared with distilled water treated group, MFCS = methanol fraction of *Callichilia subsessilis*

Table 2. Effects of MFCS against ethanol-induced gastric ulcer

Treatment	Ulcer number	Ulcer score	Ulcer index	% inhibition
Distilled water 5 ml/kg	5.00 ± 3.13	5.90 ± 3.14	7.09 ± 0.65	-
Misoprostol 50 µg/kg	0.60 ± 0.40	0.60 ± 0.40*	4.12 ± 0.08*	41.71
MFCS 12.5 mg/kg	1.80 ± 0.92	2.00 ± 1.05	4.38 ± 0.20*	38.22
MFCS 25 mg/kg	0.80 ± 0.49	0.80 ± 0.49*	4.16 ± 0.10*	41.33
MFCS 50 mg/kg	1.40 ± 0.75	1.40 ± 0.75	4.28 ± 0.15*	39.63

*P < 0.05 when compared with distilled water treated group, MFCS = methanol fraction of *Callichilia subsessilis*

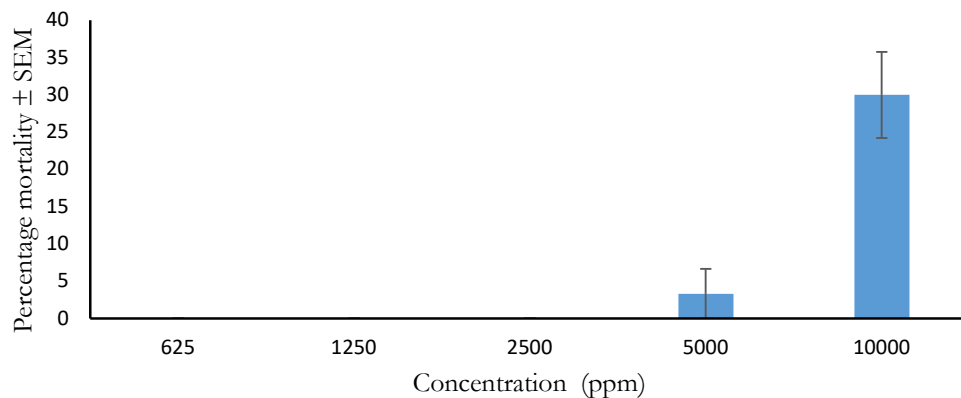


Figure 1. Brine shrimp's lethality test

MFCS = methanol fraction of *Callichilia subsessilis*, ppm = parts per million

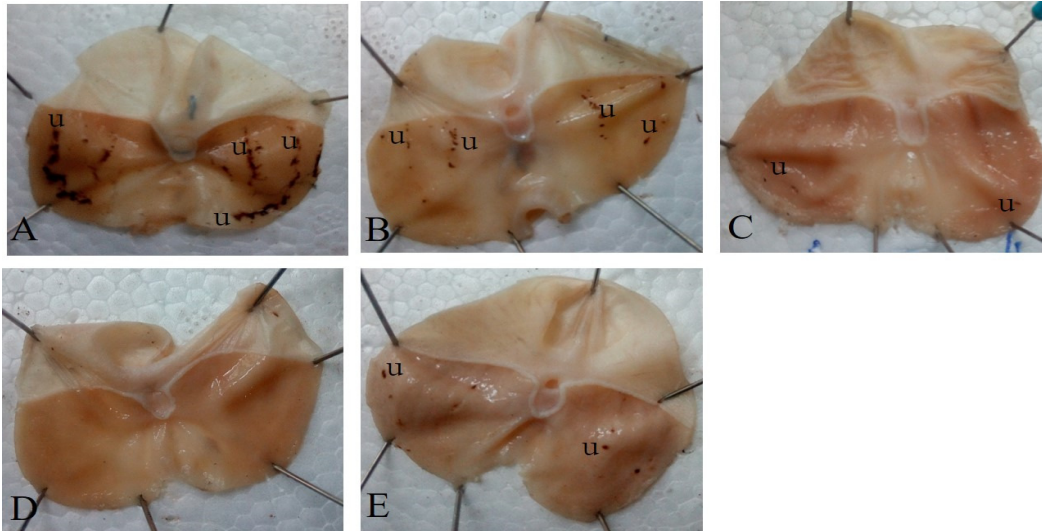


Figure 2. Gross morphology of stomach of indomethacin-induced gastric ulcer in rats
Legend: “U” = ulcer lesion, A = Distilled water 5 ml/kg, B = Misoprostol 50 µg/kg, C =MFCS 12.5 mg/kg, D = MFCS 25 mg/kg, E = MFCS 50 mg/kg

Histological sections of the stomach of indomethacin-induced gastric ulcer in rats

The photomicrograph of the histological sections of the stomach of indomethacin-induced gastric ulcer is presented in Figure 3. The letters ‘U’ and ‘M’ denotes ulcer lesion and mucosa layer, respectively. Figure 3A (distilled water treated group) had deeper and larger areas of ulceration relative to other treatment groups. Figure 3E (50 mg/kg MFCS treated group) had smaller and shallower areas of ulceration whereas Figures 3B-3D showed normal stomach section.

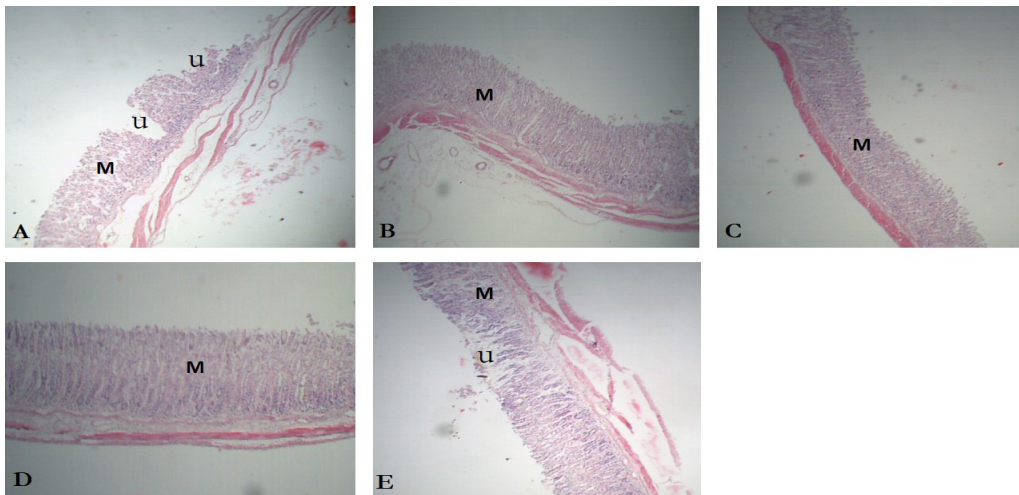


Figure 3. Histological section of the stomach of indomethacin-induced gastric ulcer in rats
Legend: “U” = ulcer lesion, “M” = mucosa, A = Distilled water 5 ml/kg, B = Misoprostol 50 µg/kg, C =MFCS 12.5 mg/kg, D = MFCS 25 mg/kg, E = MFCS 50 mg/kg

Gross morphology of stomach of ethanol-induced gastric ulcer in rats

The gross morphology (photograph) of the stomach of ethanol-induced ulcer in rats are present in Figure 4. Figure 4A (distilled water-treated group) showed larger areas of ulceration relative to the other treatment groups, while Figure 4C and 4E, MFCS 12.5 and 50 mg/kg treated groups, respectively showed fewer

areas of ulceration relative to the distilled water treated group. Misoprostol and MFCS 25 mg/kg treated groups (Figure 4B and 4D) showed no area of ulceration.

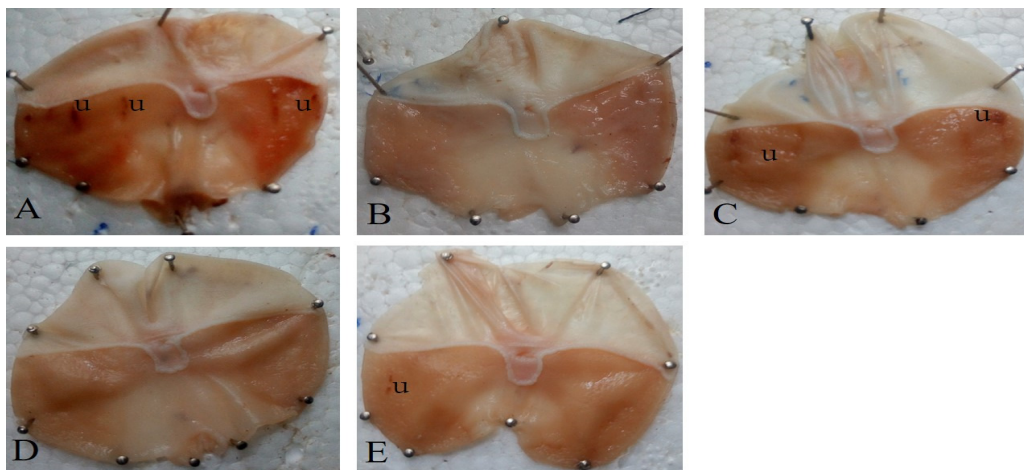


Figure 4. Gross morphology of stomach of ethanol-induced gastric ulcer in rats

Legend: "U" = ulcer lesion, A = Distilled water 5 ml/kg, B = Misoprostol 50 µg/kg, C = MFCS 12.5 mg/kg, D = MFCS 25 mg/kg, E = MFCS 50 mg/kg

Effects of MFCS against isolated rabbit jejunum

The MFCS elicited ($p < 0.05$) concentration-dependent decrease in the amplitude of a spontaneously contracting rabbit jejunum in Tyrode's solution. It also partially inhibited acetylcholine- and histamine-induced increase in the contraction of a rhythmic contracting rabbit jejunum (Figure 5).

Discussion

This study interrogated the anti-ulcer property of MFCS and its possible mechanism of action. MFCS reduced ($p < 0.05$) ulcer lesion in indomethacin- and ethanol-induced gastric ulcer in rats and also diminished the rhythmic contraction of isolated rabbit jejunum in a Tyrode's solution. It partially inhibited histamine- and acetylcholine-induced contraction of the smooth muscle of isolated rabbit jejunum.

Ethanol induces gastric ulcer via the elevated release of gastric acid, free radical and pepsin, as well as declined bicarbonate and mucus production (Sistani *et al.*, 2019). These conditions make the gastric mucosa vulnerable to the deleterious effects of the offensive factors that predispose to gastric ulceration (Sahoo *et al.*, 2016). Indomethacin causes gastric ulceration via inhibition of cyclooxygenase activity, declined prostaglandin, mucus and bicarbonate production, reduced gastric blood flow and elevated free radical release (Sabiou *et al.*, 2015). The decreased ulcer lesions in the MFCS-treated groups suggest that some of the biochemical processes implicated in ethanol- and indomethacin-induced ulcer were inhibited and MFCS possess anti-ulcer activity (Sabiou *et al.*, 2015; Sahoo *et al.*, 2016; Sistani *et al.*, 2019).

Free radicals and lipid peroxidation play a pivotal role in the pathogenesis of indomethacin- and ethanol-induced gastric ulcer (Sabiou *et al.*, 2015; Sahoo *et al.*, 2016; Sistani *et al.*, 2019). Antioxidants mop up free radicals and inhibit lipid peroxidation thus, useful in the amelioration of gastric ulcer (Salami *et al.*, 2018). The anti-ulcer activity of MFCS could be linked to its antioxidant potentials. The anti-ulcer effects of *Punica granatum*, *Aegle marmelos* and *Allium sativum* were attributed to their antioxidant properties (Harsha *et al.*, 2017).

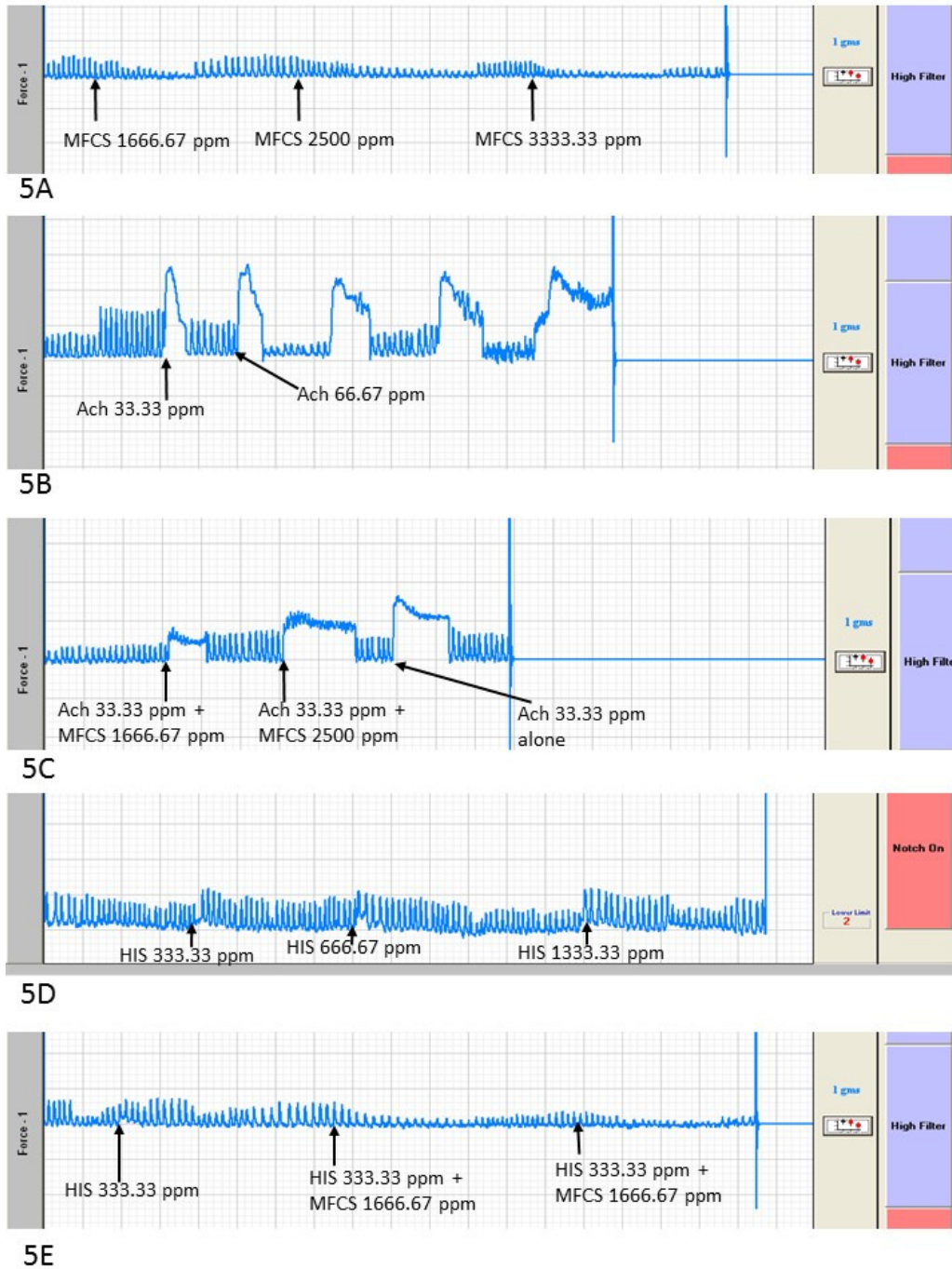


Figure 5. Effects of MFCS against isolated rabbit jejunum

Legend: 5A = MFCS alone, 5B = acetylcholine (Ach) alone, 5C = MFCS and acetylcholine (Ach), 5D = histamine (HIS) alone, 5E = MFCS and histamine (HIS), MFCS = methanol fraction of *Callichilia subsessilis*

The MFCS partially inhibited histamine and acetylcholine-induced contraction of isolated rabbit jejunum. This suggests that it possesses antihistaminic and anticholinergic properties and would act as an antisecretory agent (da Silva *et al.*, 2018). Histamine (H₂) and acetylcholine receptor abound in the intestinal mucosa and are involved in the synthesis and secretion of gastric acid as well as control of gastrointestinal motility (Takeuchi *et al.*, 2016). Antisecretory agents impair the activity of hydrogen-potassium adenosine triphosphatase (H⁺-K⁺ ATPase) and H₂ receptor which are involved in the secretion of gastric acid (Lundell, 2015; Takeuchi *et al.*, 2016). Histamine (H₂) receptor antagonists (cimetidine and ranitidine) are employed in the treatment of gastric ulcer (Harsha *et al.*, 2017). The antihistaminic effect of one of the constituents of MFCS (cyclohexanone) has been documented (Nabil *et al.*, 2018). Anti-ulcer effects of *Ficus glomerata* and *Solanum nigrum* is attributed to the inhibition of H⁺-K⁺ ATPase (Harsha *et al.*, 2017). Anticholinergic agents delay gastrointestinal emptying time and decrease the secretion of gastric acid and pepsin, thus ameliorate gastric ulcer.

The anti-ulcer activity of MFCS compared favorably with misoprostol and this suggests that they might have an identical mechanism of action. Misoprostol is a prostaglandin (PGE-1) analogue that stimulate mucus and bicarbonate production. It also protects the epithelial layer integrity by eliciting vasodilation and enhanced mucosal blood circulation (Sařaga and Mosińska, 2017). The MFCS might have stimulated prostaglandins production.

Conclusions

This study validated the use of *Callichilia subsessilis* leaf in the traditional treatment of gastric ulcer. It might have multiple mechanisms of action such as antihistaminic, anticholinergic, enhanced prostaglandin production and antioxidation effects. We recommend further studies geared towards isolation of active principle and elucidation of the mechanism of action.

Authors' Contributions

SOO, GCE and DU were involved in the conceptualization, design, execution, draft and review of the manuscript; CBCI drafted and review the manuscript; JIU, KGM and PEA participated in the design, sourcing of material, statistical analysis and review of manuscript while NEU and MIE were involved in the supervision, review and editing of the manuscript.

All authors read and approved the final manuscript.

Ethical approval

The experimental protocol was approved by the institutional Animal Ethics Committee of the College of Veterinary Medicine, Michael Okpara University of Agriculture Umudike.

Acknowledgements

The authors are grateful to Mr. Ndukwe Ibeh for the identification of the plant.

Conflict of Interests

The authors declare that there are no conflicts of interest related to this article.

References

- Albaqawi AS, el-Fetoh NM, Alanazi RF, Alanazi NS, Alrayya SE, Alanazi AN, ... Ali WM (2017). Profile of peptic ulcer disease and its risk factors in Arar, Northern Saudi Arabia. *Electronic Physician* 9(11):5740-5745. <http://dx.doi.org/10.19082/5740>
- Balan T, Mohd. Sani MH, Suppaiah V, Mohtarrudin N, Suhaili Z, Ahmad Z, Zakaria ZA (2014). Antiulcer activity of *Muntingia calabura* leaves involves the modulation of endogenous nitric oxide and nonprotein sulfhydryl compounds. *Pharmaceutical Biology* 52(4):410-418. <https://doi.org/10.3109/13880209.2013.839713>
- da Silva LM, de Moura BL, Crestani S, de Souza P, Dartora N, de Souza LM, ... de Paula WMF (2018). Acid-gastric antisecretory effect of the ethanolic extract from *Arctium lappa* L. root: role of H⁺, K⁺-ATPase, Ca²⁺ influx and the cholinergic pathway. *Inflammopharmacology* 26(2):521-530. <https://doi.org/10.1007/s10787-017-0378-4>
- Fallone CA, Chiba N, van Zanten SV, Fischbach L, Gisbert JP, Hunt RH, ... Marshall JK. The Toronto consensus for the treatment of *Helicobacter pylori* infection in adults. *Gastroenterology* 151(1):51-69. <https://doi.org/10.1053/j.gastro.2016.04.006>
- Harsha C, Banik K, Bordoloi D, Kunnumakkara AB (2017). Antiulcer properties of fruits and vegetables: A mechanism based perspective. *Food and Chemical Toxicology* 108:104-119. <https://doi.org/10.1016/j.fct.2017.07.023>
- Lanas A, Chan FK (2017). Peptic ulcer disease. *The Lancet* 390(10094):613-624. [https://doi.org/10.1016/S0140-6736\(16\)32404-7](https://doi.org/10.1016/S0140-6736(16)32404-7)
- Lundell L (2015). The physiological background behind and course of development of the first proton pump inhibitor. *Scandinavian Journal of Gastroenterology* 50(6):680-684. <https://doi.org/10.3109/00365521.2015.1013981>
- Malfertheiner P, Megraud F, O'morain CA, Gisbert JP, Kuipers EJ, Axon AT, ... Hunt R (2017). Management of *Helicobacter pylori* infection-the Maastricht V/Florence consensus report. *Gut* 66(1):6-30. <http://dx.doi.org/10.1136/gutjnl-2016-312288>
- Nabil S, Abd El-Rahman SN, Al-Jameel SS, Elsharif AM (2018). Conversion of curcumin into heterocyclic compounds as potent anti-diabetic and anti-histamine agents. *Biological and Pharmaceutical Bulletin* 41(7):1071-1077. <https://doi.org/10.1248/bpb.b18-00170>
- Onoja SO, Ikwuagwu EO, Ezeigbo II, Madubuike KG, Omeh YN, Anaga AO, Ezeja MI (2018). Preliminary investigation of the possible antiinflammatory and antioxidant activities of extract of *Callichilia subsessilis* Stapf. (Apocynaceae). *Tropical Journal of Natural Product Research* 2(1):34-37. <https://doi.org/10.26538/tjnpr/v2i1.7>
- Paguigan ND, Castillo DHB, Chichioco-Hernandez CL (2014). Anti-ulcer activity of leguminosae plants. *Arquivos de Gastroenterologia* 51(1):64-68. <https://doi.org/10.1590/S0004-28032014000100013>
- Raskin I, Ribnicky DM, Komarnytsky S, Ilic N, Poulev A, Borisjuk N, ... O'Neal JM (2002). Plants and human health in the twenty-first century. *Trends in Biotechnology* 20(12):522-531. [https://doi.org/10.1016/S0167-7799\(02\)02080-2](https://doi.org/10.1016/S0167-7799(02)02080-2)
- Sabiu S, Garuba T, Sunmonu T, Ajani E, Sulyman A, Nurain I, Balogun A (2015). Indomethacin-induced gastric ulceration in rats: protective roles of *Spondias mombin* and *Ficus exasperata*. *Toxicology Reports* 2:261-267. <https://doi.org/10.3109/13880209.2015.1029050>
- Sahoo SK, Sahoo HB, Priyadarshini D, Soundarya G, Kumar CK, Rani KU (2016). Antiulcer activity of ethanolic extract of *Salvadora indica* (W.) leaves on albino rats. *Journal of Clinical and Diagnostic Research* 10(9):FF07-FF10. <https://doi.org/10.7860/JCDR/2016/20384.8470>
- Salaga M., Mosińska P (2017). Pharmacological treatment of peptic ulcer disease. In: Fichna J. (Ed). *Introduction to Gastrointestinal Diseases Vol. 2*. Springer, Cham. https://doi.org/10.1007/978-3-319-59885-7_5
- Salami AT, Odukanmi OA, Faniyan OF, Omayone TP, Olaleye SB (2018). Seeds of *Buchholzia coriacea* in diet mitigate ischemic reperfusion-induced gastric ulceration in experimental rats. *Journal of Dietary Supplements* 15(6):842-59. <https://doi.org/10.1080/19390211.2017.1404544>

- Sayehmiri K, Abangah G, Kalvandi G, Tavan H, Aazami S (2018). Prevalence of peptic ulcer in Iran: Systematic review and meta-analysis methods. *Journal of Research in Medical Sciences* 23:8 https://doi.org/10.4103/jrms.JRMS_1035_16
- Sistani K N, Arzi A, Rezaie A, Pashmforoosh M, Kordi F (2019). Gastroprotective effect of zingerone on ethanol-induced gastric ulcers in rats. *Medicina* 55(3):64. <https://doi.org/10.3390/medicina55030064>
- Takeuchi K, Endoh T, Hayashi S, Aihara T (2016). Activation of muscarinic acetylcholine receptor subtype 4 is essential for cholinergic stimulation of gastric acid secretion: relation to D cell/somatostatin. *Frontiers in Pharmacology* 7:278. <https://doi.org/10.3389/fphar.2016.00278>
- Zabidi Z, Zainulddin WW, Mamat SS, Din SS, Kamisan FH, Yahya F, ... Somchit MN (2012). Antiulcer activity of methanol extract of *Melastoma malabathricum* leaves in rats. *Medical Principles and Practice* 21(5):501-503. <https://doi.org/10.1159/000337406>



The journal offers free, immediate, and unrestricted access to peer-reviewed research and scholarly work. Users are allowed to read, download, copy, distribute, print, search, or link to the full texts of the articles, or use them for any other lawful purpose, without asking prior permission from the publisher or the author.



License - Articles published in *Notulae Scientia Biologicae* are Open-Access, distributed under the terms and conditions of the Creative Commons Attribution (CC BY 4.0) License.

© Articles by the authors; SHST, Cluj-Napoca, Romania. The journal allows the author(s) to hold the copyright/to retain publishing rights without restriction.